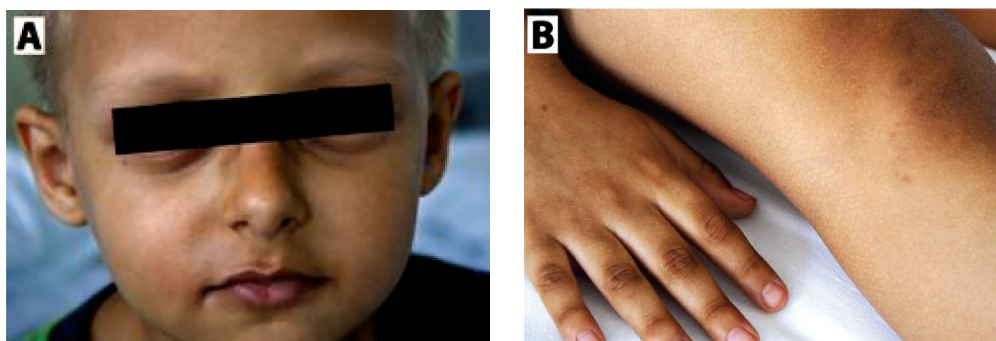


ADDISON DISEASE – CASE REPORT

Rade VUKOVIĆ, Dragan ZDRAVKOVIĆ¹, Tatjana MILENKOVIĆ, Slađana TODOROVIĆ

Institute for Mother and Child Health Care of Serbia “Dr Vukan Čupić”, Belgrade
School of Medicine, University of Belgrade¹
e-mail: rade.vukovic@live.com; Tel.: +381 11 3108 109



A 6-year-old boy was admitted to our hospital due to high fever (41.0°C), malaise, diminished appetite and sense of thirst. Because of toothache and swelling of the right cheek one day prior to admission he was examined by the local pediatric dentist and prescribed antibiotic therapy. The boy presented with fatigue, his body height was measured as 114.0 cm, body weight 16.0 kg and his body mass index for age and gender was below the 3rd percentile (12.31 kg/m²). Examination revealed swelling of the right cheek which was 5 cm in diameter and general skin hyperpigmentation (Figure A) accentuated in the area of skin folds and scar tissue (Figure B). The parents had noticed darker skin tone since he was three years old. During the previous months they also noticed that he was fatigued and craving for salty food. Laboratory investigations revealed low serum sodium level (123 mmol/l) accompanied by hypernatruria (132 mmol/l; normal range value ≤ 20 mmol/l), normal serum potassium level (5.1 mmol/l), low serum aldosterone level (2.4 ng/dl; normal range value: 3 – 35 ng/dl), compensated metabolic acidosis (pH 7.373, pCO₂ 30.0 mmHg, HCO₃⁻ 17.1 mmol/l, SBE -7.2 mmol/l) and very low serum cortisol level (< 10 nmol/l) with no increase in plasma cortisol level following cosyntropin stimulation (all levels measured during a stimulation test were less than 10 nmol/l). Physical examination and laboratory findings confirmed the diagnosis of Addison disease recognized in the acute adrenal crisis provoked by acute periodontal infection. Immediately upon admission, parenteral correction of fluid and electrolyte imbalances, glucocorticoid and mineralocorticoid substitution and antibiotic therapy were started. After the patient was stabilized, the affected tooth was extracted and permanent hydrocortisone and fludrocortisone replacement therapy was started.