

Non-operative Reduction of Intussusception in 16-Month-Old Boy with Sudden Episode of Hemorrhaging Deterioration via Reperfusion of Meckel's Diverticulum: Case Report

Yuliya Modna¹, Ievgen Mozhaiev², Natalia Mozhaieva², Allen Barbarovich¹, Mariya Klauber¹

¹Department of Physiology, Trinity Medical Sciences University, Roswell, GA, USA, Saint Vincent and the Grenadines Campus, Kingstown, ²Department of Pediatric Surgery, Chechen Federal University, Medical Institute, Grozny, Russian Federation

Correspondence: ymodna@trinityschoolofmedicine.org; Tel.: + 1 784 496 0 896; Fax.: + 1 784 456 9 751

Received: July 15, 2020; **Accepted:** October 26, 2020

Abstract

Objective – The aim of this study is to report a rare clinical case of a 16-month-old boy with a sudden episode of hemorrhaging deterioration, which required immediate laparotomy 14 hours after a successfully performed non-surgical reduction of intussusception. Inflamed Meckel's diverticulum was identified as the cause of hemorrhage due to the reperfusion of this region of the intestine after the invagination was resolved. **Case Report** – A 16-month-old boy was presented to the emergency department with the signs and symptoms of acute intestinal invagination, which were visually confirmed by ultrasound. The successful reduction of intussusceptions by air enema was performed and confirmed by ultrasound. On physical examination five hours after the gas enema procedure patient had no complaints, and no signs or symptoms of peritoneal irritation. However, 14 hours after the reduction of intussusception patient developed signs of hemorrhage, which suggested the presence of hemorrhaging Meckel's diverticulum due to a reperfusion of that region of intestine. **Conclusion** – Despite the successful use of nonsurgical methods of disinvagination, it remains critical for the management team to keep in mind that one of the predisposing factors of acute intestinal invagination such as Meckel's diverticulum can cause post therapeutic complications, manifesting as acute hemorrhage.

Key Words: Intestinal Intussusception ■ Meckel's Diverticulum ■ Air Enema ■ Ischemia-Reperfusion Injury ■ Hemorrhage.

Introduction

Intussusception is a frequent cause of intestinal obstruction in early childhood, which is a medical emergency that requires prompt diagnosis and management (1). Approximately 5% of patients with invagination are found to have some kind of predisposing factors. One of the primary factors is Meckel's diverticulum, which is the most common congenital abnormality of the gastrointestinal tract (2). The gold standard treatment of intussusceptions in children is a nonsurgical reduction of invagination by enema (with air or liquid) (3). This method is successful in 77% (95% confidence interval, 72% to 82%) of all cases of intussusceptions.

Following successful reduction of the intussusceptions, early recurrence is rare, with rates ranging from 2.7% to 5.4% (3).

We report here a rare clinical case of a 16-month-old boy with a sudden episode of hemorrhaging deterioration, which required immediate laparotomy 14 hours after a successfully performed non-surgical reduction of intussusception.

Clinical Case

A 16 month-old child presented to the GBU Clinic emergency in the city of Grozny, Russia, with the fever, vomiting, and bloody stool. The parents reported that the child had numerous episodes of

vomiting (more than 5 instances per day) for the last two days, the presence of mucus and dark blood impurities in the feces, and fever reaching 38 °C. Two days prior the hospitalization the child began to refuse food, developed a fever, spastic abdominal pain and had a loose stool. On physical examination the patient was in moderate to severe distress and responded to examination with cries. The body temperature was 38 °C, HR of 136 bpm, BP of 90/60 mmHg, and RR of 38 respirations per minute. Patient's abdomen was tender on palpation with painful sensitivity localized to the right mesogastric region. A moderately mobile mass was localized in the right mesogastric region upon palpation, about 8.0 × 5.0 cm in size, with a dense consistency that rebounds with moderate elasticity. Cutaneous percussion of the liver met with expected dullness without indications of hepatomegaly, abnormal perfusion or edema. No symptoms of peritoneal irritation were observed. Test for Dance's sign was positive for retraction of the right lower quadrant, suggesting intussusception. Examination of rectum indicated diminished sphincteric tone, and a vacant rectal ampulla. Neither pain nor overhanging of rectal boundaries or rectocele was detected on exam. After physical exam, a stool sample was collected with a characteristic "red currant jelly," presentation. Ultrasound visually confirmed diagnosis of acute intestinal intussusception. Laboratory results showed the following: Hb - 80 g/L, RBC- 2.9 × 10¹²/L, WBC- 7.5 × 10⁹/L, (band NE-3%, segmented NE-67%, LY- 25%, MO- 5%), PLT- 2.6 × 10⁹/L, ESR 8 mm/h. Total protein - 53.97 g/L, creatinine - 48.88 mmol/L, urea - 3.14 mmol/L, C-reactive protein - 5.11 mg/L. Blood type and Rh factor: B (III), Rh (+) positive. Urinalysis: color - net yellow, transparency - cloudy, specific gravity - 1.012, pH - acidic, protein - negative, sugar - negative, ketones - negative, salt - negative, mucus - negative.

Considering the history of presenting illness and the age of the patient, the decision was made to perform an air enema (an oxygen pressure of 60 mm/Hg pressure was used) under general intravenous anesthesia, tracheal intubation, and mechani-

cal ventilation. Before the enema procedure the resuscitation was conducted by 200 ml of sodium chloride 0.9% solution and 400 ml of Ringers solution. A distinct thump was elicited on resolution of the intussusception, once the pressure change ameliorated itself with bimanual surgeon's control. Air was liberated from the intussusception along the nasogastric tube.

On physical exam two hours after the air enema procedure, the patient was conscious, in mild discomfort without nausea or vomiting, with a body temperature of 37.5° C, HR of 128 bpm, BP of 92/64 mmHg, and RR of 32 respirations/min and with a healthy pale pink perfused skin color. Abdomen was soft, non-responsive to palpation, and the mass was no longer palpable. There were no signs or symptoms of peritoneal irritation. The stool and normal post-therapeutic procedure gas accumulation in the lumen of the intestine showed appropriate evidence of healthy gas exchange and reduction in volume. Ultrasound visually confirmed absence of intestinal intussusception. Five hours after the procedure, the patient did not have any complaints. The abdomen examination was negative for evidence of pathological stricture or reformation. There were no signs or symptoms of peritoneal irritation and intestinal motility was consistent with normal peristaltic behavior. Stool was sparse and speckled with green deposits. Fourteen hours after the procedure the patient had blood in the diaper (Fig. 1.) presenting as cherry red clots and manifested in increasing discomfort. The patient's abdomen was soft and negative for evidence of pathological stricture or presence of intussusception, which was also confirmed by the ultrasound, but the patient reacted sharply as to severe pain on abdominal palpation. The intestinal motility was consistent with normal peristaltic behavior, and easily auscultated.

So, based on the results of ultrasound, which confirmed the absence of intestinal intussusception, the appearance of a hemorrhage (Fig. 1) which was seen fourteen hours after the reduction of intussusception and the fact from a literature review that the one of main causes of the intestinal intussusception in children of this age is Meckel's diverticulum

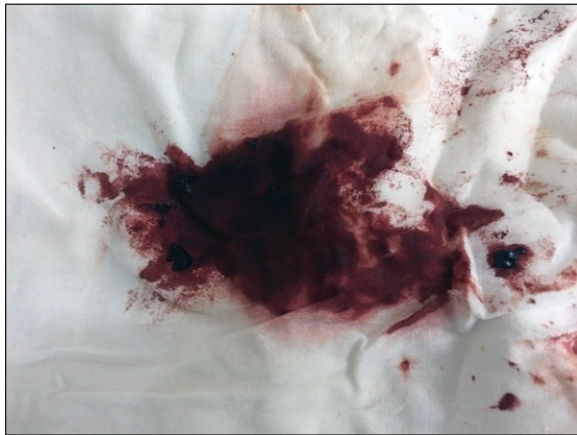

Fig. 1. The Appearance of Hemorrhage on Patient's Diaper the 14 Hours after the Enema Procedure.

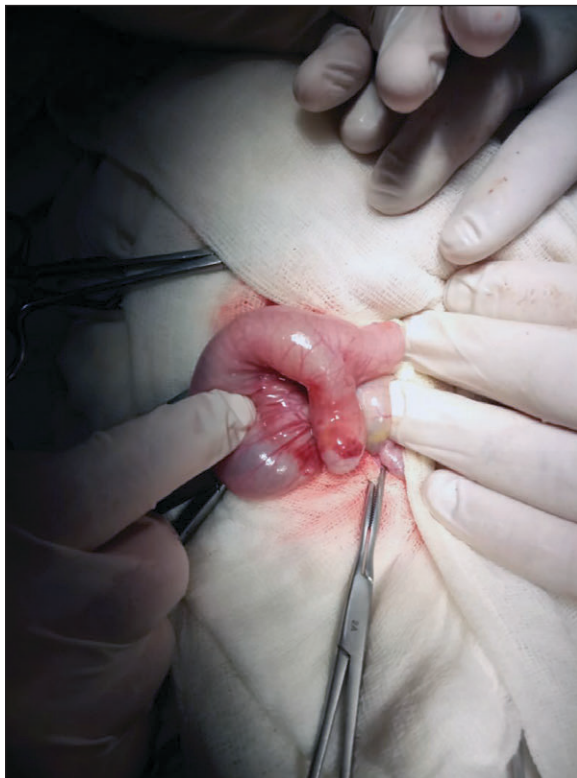

Fig. 2. Hemorrhaging Meckel's Diverticulum.

a preliminary diagnosis of Meckel's diverticulum bleeding was established. Considering the patient age, condition, and emergent prognosis, the decision was made to establish interventional care and proceed with surgical correction as follows: access to the peritoneal cavity was made via laparoscopic

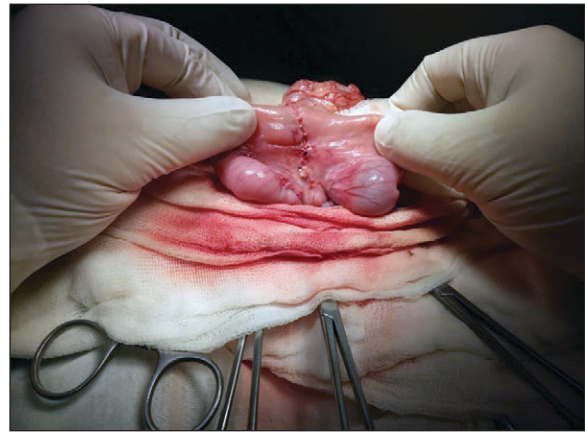


Fig. 3. Site of the Resection of Meckel's Diverticulum and the Application of a Small Intestinal "End to End" Anastomosis.

route, peritoneal organs were appropriately revised to localize the previous intussusceptions site and liberate it from its immediate vascular supply, the resection of the Meckel's diverticulum, and the drainage of the peritoneal cavity (Fig. 2).

Meckel's diverticulum was found 70 cm away from the ileocecal angle located closer to the mesenteric edge of the small intestine on a wide stalk. After mobilization of the mesentery of the diverticulum (the latter is clamped, stitched, tied off, and cut), Meckel's diverticulum was resected with application of a small intestinal "end to end" anastomosis (Fig. 3).

The post-operational period passed smoothly. The stitch was removed on the tenth post-operational day. The histologic result was received after the surgery which confirmed the diagnosis of diverticulum of small intestine and chronic diverticulitis. The child was discharged on the 11th day in satisfactory condition

Discussion

Idiopathic intussusception most frequently occurs in children younger than age three, but almost half of the cases of intussusceptions secondary to Meckel's diverticulum have been reported in patients over the age of three (2). Meckel's diverticulum is usually asymptomatic throughout life and causes

symptoms in only 1% of patients. The most common manifestation is a low gastrointestinal bleeding and less frequent are intussusceptions, intestinal obstruction or diverticulitis (5, 6).

Non-surgical management of intussusceptions in children consists of contrast enema (3). This method is based on the instilling contrast medium (i.e. air, saline, or barium) into the rectum via a rectum tube to reduce the intussusceptum by increasing intraluminal pressure. Air enema is considered as the gold standard treatment of intussusceptions in children and its use has increased due to a lower perforation risk, faster and better reduction rate in comparison with a barium enema (3). The data of one study showed that the success rate of air vs. contrast enema was 77% and 63% respectively (3, 4). The technique of reduction consists of up three attempts, each for a maximum of 3 minutes. Usually the nonsurgical treatment by air enema is unsuccessful if the patient has a pathologic lead points (such as Meckel's diverticulum, lymphoid hypertrophy, duplication cyst, polyp, and lymphoma (1, 3). Surgical intervention is needed only if the patient is unstable with non-operative reduction contraindications (peritonitis, bowel perforation, shock) or in prior unsuccessful reduction attempts.

Intussusception is a cause of downstream ischemia and in any case of ischemic resolution, the potential for reperfusion injury should be addressed. Intestinal ischemia-reperfusion (I/R) injury is a direct result of a variety of pathophysiological mechanisms by which the restoration of blood flow through mesenteric vessels that were previously occluded by an intussusceptum such as the one in this case, results in intestinal damage. Reperfusion following ischemia can further exacerbate damage of the intestine. Though not fully elaborated, the mechanism by which reperfusion injury damages intestinal tissues is thought to be related to a biphasic pattern of pathophysiological events. Mucosal barrier function is destroyed and vascular permeability is increased during the formation of the I/R injury. This allows the activation of inflammatory cells, which release reactive oxygen species and promote the elaboration of proinflammatory

chemokines and cytokines that recruit an aggressive immune response that is both humoral and cell mediated to the region of reperfusion, developing complications in previously injured tissue (7, 8). The damaged intestinal barrier can also cause bacteria to penetrate the intestinal mucosa and submucosa after I/R injury and the bacterial translocation stimulates inflammatory cells to release proinflammatory cytokines (9, 10).

To the best of our knowledge, the complication after a successful reduction of intussusception by the air enema is uncommon in the pediatric surgery. The reduction of intussusceptions in our patient was confirmed by ultrasound and on physical exam five hours after the gas enema procedure patient had no complaints, signs, or symptoms of peritoneal irritation. Only fourteen hours after the reduction of intussusception patient developed signs of hemorrhage, which suggested the presence of hemorrhaging Meckel's diverticulum due to a reperfusion of that region of intestine.

Limitations of the Study

The proper diagnostic test was not performed before the surgery and the decision to proceed with surgery was based on the own surgical experience and clinical findings.

Conclusion

Despite the successful use of nonsurgical methods of disinvagination it remains critical for the management team to keep in mind that one of the predisposing factors of acute intestinal intussusception such as Meckel's diverticulum can cause post therapeutic complications, manifesting as acute hemorrhage. The use of ultrasound for intestinal intussusception diagnosis is one of the primary instrumental diagnostic and treatment decision techniques. However, in this clinical situation the diagnostic value of ultrasound is significantly reduced. As a result, this case further substantiates the imperative for hemodynamic monitoring of patients who undergo conservative treatment within the initial 72

hours to prevent catastrophic outcomes that could have been appropriately and effectively addressed as they were in this case.

Conflict of Interest: The authors declare that they have no conflict of interest.

References

1. Hadidi AT, El - Shal - N. Childhood intussusception: a comparative study of nonsurgical Management. *J Pediatr Surg.* 1999;34(2):304-7.
2. Anduaga EO, Julca AO, Tantalean JR. Case Reports of Atypical Presentation of Meckel's Diverticulum. *Rev Colomb Gastroenterol.* 2017;32(2):161-4. doi:10.22516/25007440.144.
3. Gluckman S, Karpelowsky J, Webster AC, McGee RG. Management for intussusception in children. *Cochrane Database Syst Rev.* 2017 Jun 1;6(6):CD006476. doi:10.1002/14651858.CD006476.pub3.
4. Pineda C, Hardasmalani M. Pediatric intussusception: A Case Series and Literature Review. *Internet J Pediatr Neonatol.* 2008;11(1):1-12.
5. Ugwu BT, Legbo JN, Dakum NK, Yiltok SJ, Mbah N, Uba FA. Childhood intussusception: a 9-year review. *Ann Trop Paediatr.* 2000;20(2):131-5. doi:10.1080/02724936.2000.11748122.
6. Harrington L, Connolly B, Hu X, Wesson DE, Babyn P, Schuh S. Ultrasonographic and clinical predictors of intussusception. *J Pediatr.* 1998 May;132(5):836-9. doi:10.1016/s0022-3476(98)70314-2.
7. Eltzschig HK, Eckle T. Ischemia and reperfusion--from mechanism to translation. *Nat Med.* 2011; 17:1391-401.
8. Lee H, Ko EH, Lai M, Wei N, Balroop J, Kashem Z, et al. Delineating the relationships among the formation of reactive oxygen species, cell membrane instability and innate autoimmunity in intestinal reperfusion injury. *Mol Immunol.* 2014;58(2):151-9. doi:10.1016/j.molimm.2013.11.012.
9. Perez-Chanona E, Muhlbauer M, Jobin C. The microbiota protects against ischemia/ reperfusion-induced intestinal injury through nucleotide-binding oligomerization domain-containing protein 2 (NOD2) signaling. *Am J Pathol.* 2014; 184:2965-75.
10. Yoshiya K, Lapchak PH, Thai TH, Kannan L, Rani P, Dalle Lucca JJ, et al. Depletion of gut commensal bacteria attenuates intestinal ischemia/reperfusion injury. *Am J Physiol Gastrointest Liver Physiol.* 2011;301(6):G1020-30. doi: 10.1152/ajpgi.00239.2011.