

The Foot-Gotten Variable – Modified Assessment for Measuring the Rotational Profile

Sam Khamis^{1,2}, Moran Arad¹, Ben Nouriel⁵, Roea Hayek⁵, Barry Danino^{3,4}

¹Gait and Motion Analysis Laboratory, Department of Pediatric Orthopedics, Dana Children's Hospital, Tel Aviv Sourasky Medical Center, Tel Aviv, Israel; ²Imacs – Israeli Motion Analysis Center for Sports, Tel-Aviv, Israel; ³Department of Pediatric Orthopedics, Dana Children's Hospital, Tel Aviv Sourasky Medical Center, Tel Aviv, Israel; ⁴Faculty of Medicine, Tel-Aviv University, Tel-Aviv, Israel; ⁵Ariel University Department of Physiotherapy, Ari'el, Israel

Correspondence: khamisam@gmail.com; arad.moran@gmail.com; Tel.: + 972 3 6947279; Fax.: + 972 3 6947280

Received: December 6 2023; **Accepted:** March 11 2024

Abstract

The assessment of the rotational profile in the lower limb involves the evaluation of both the tibia and femur. Common methods for assessing tibial torsion include the Transmalleolar Axis (TMA) and Thigh Foot Angle (TFA). While TMA and TFA are highly reliable, their validity is limited, often overlooking a crucial variable – the foot. External rotated TFA is typically linked to a pronated foot, while a supinated foot is associated with internal rotated TFA. This association arises from foot alignment, rendering the measurement not truly reflective of tibial torsion. We propose measuring tibial torsion in subtalar neutral and in a simulated weight-bearing position to address the impact of foot alignment on TFA measurement. **Conclusion** – This innovative approach to TFA measurement has the potential to enhance diagnostic accuracy in clinical settings, thereby improving clinical decision making regarding treatment choices. Short Title. Modified Assessment for Foot Thigh Angle

Key Words: Thigh Foot Angle ■ Tibial Torsion ■ Femoral Anteversion ■ Subtalar Neutral ■ Rotational Profile.

Introduction

Deviation in the rotational profile can indicate significant alignment deformities, potentially contributing to various musculoskeletal issues, including knee pain (1, 2, 3, 4) and abnormal rotational movement and alignment (5, 6, 7). A reliable physical examination of the rotational profile is invaluable for precisely identifying the origin of these abnormalities, enabling the formulation of tailored treatment strategies (8, 9, 10). The measurement of the rotational profile serves as a crucial diagnostic tool, particularly in individuals with cerebral palsy (CP) and children displaying excessive internal or external foot progression angles (FPA) (9, 10, 11). This profile comprises two integral components: the femur and tibia (9, 10, 12). A meticulous assessment of the rotational profile not only enhances our comprehension of deformities' origins

but also facilitates the prescription of appropriate treatments, ensuring optimal care for the patient.

This short communication aims to conduct a literature review on current methods for measuring tibial torsion while introducing a novel approach to assess thigh foot angle. The proposed method holds the potential to enhance diagnostic accuracy in clinical settings, thereby contributing to improved clinical decision-making regarding treatment choices. Moreover, this innovative approach will also evaluate the influence of foot alignment on the foot progression angle.

Measuring Femoral and Tibial Torsion

Femoral torsion is measured with Craig's test (also known as Ryder's test). The patient is positioned prone, with the knee flexed to 90°. The greater

trochanter is palpated as the hip is rotated externally until it reaches its maximum prominence (13). Another method for assessing femoral torsion is by finding the difference between internal and external hip rotation in prone. When internal/external rotation is significantly different, femoral anteversion or retroversion is suspected (14). *Tibial torsion* is measured by the TMA. The patient lies prone, with the knee flexed to 90° while the examiner sites both malleoli and measures the angle created between the line bisecting the malleoli and the line down the midline of the femur (15).

Originally described by Engel and Staheli (8), the TFA is more commonly used: the patient lies prone, knees flexed to 90°, while positioning the feet in neutral position. However, with time and modifications, the description focused on positioning the ankle in neutral dorsiflexion (16). The examiner measures the angle between the longitudinal axis of the thigh and the foot. Engel and Staheli stated that it was measured to “roughly assess the rotational components of the tibia and the hindfoot” (8).

Reliability and Validity

Many studies found that TMA and TFA have good to high reliability (16, 17, 9, 18, 19). Despite these findings, one study (20) described an inter-observer variability of approximately 25% chance difference in TFA. However, both TMA and TFA retain low to moderate validity when compared to CT (9, 21, 18, 19) or ultrasound (17). The most important part of the measurement is to find the accurate source of the rotation. The low validity for TFA may be due to an additional variable contributing to the rotational profile – the foot.

Foot Alignment

The relatively low validity of the TFA may be due to the subtalar joint (STJ), which is responsible for inversion and eversion movements. The subtalar joint's position depends on whether the foot is in loaded (weight bearing) or unloaded (non-weight

bearing) position (22). Furthermore, due to the STJ's structure, closed kinetic chain (CKC) will provide a greater eversion measurement than open kinetic chain.

Subtalar hyper-pronation increases external FPA (23), and hyper-supination leads to excessive internal FPA. Consequently, the position of the STJ significantly alters the relationship between the foot and the thigh. External TFA manifests in a pronated foot while internal TFA is observed in a supinated foot. These deviations may therefore be a result of the foot alignment, and do not reflect tibial torsion accurately.

The forefoot's structure also plays a role in TFA measurements, and necessitates consideration: Significant forefoot adduction will present with a lesser degree of external TFA – therefore, the heel bisector line is used to evaluate for forefoot adduction or abduction. It is assessed with the patient in a prone position, and knees flexed to 90 degrees. An imaginary straight line from the heel to the forefoot typically bisects the second toe. Forefoot adduction is classified mild if the line falls on the third toe, moderate - between the third and fourth toes, and severe - between the fourth and fifth toes.

Redefining Thigh Foot Angle Measurement

We advocate for the measurement of TFA with the patient lies prone and both knees flexed to 45–90°; assessing the angle as the relationship between the foot axis and the thigh, aligning with previous recommendations (16, 8, 17, 9, 21, 18, 20, 19). However, we propose an innovative method of TFA measurement involving two distinct states:

Subtalar Joint in a Neutral Position (STN)

When measuring TFA, the examiner ensures the subtalar joint is in a neutral position through palpation. This neutral state eliminates the influence of foot alignment, providing a potentially more accurate assessment of tibial rotation.

Subtalar Joint Simulating a Loaded or Weight-Bearing Position

In this scenario, the examiner imparts force to the forefoot, allowing the foot either pronate or supinate based on the subtalar joint axial alignment and muscle imbalance. This assessment evaluates the foot's impact on the rotational profile. Notably, a prominently pronated foot in a loaded position can lead to a significantly increased external TFA. Significant differences between measurements in STN and the loaded position indicate a notable foot component. In such instances, correction for foot alignment becomes crucial.

Illustrative Case

Fig. 1a demonstrates a child with CP spastic diplegia, measuring tibial torsion using TFA while the foot is in a simulated weight-bearing position. External rotation of approximately 45° is measured. This may lead to the conclusion that tibial torsion is the source of the rotational deformity (Fig. 1a). However, measuring TFA in STN in Fig. 1b reveals a much lesser degree of external rotation (0°) (Fig. 1b). This emphasizes the role of the foot in the external rotation profile and one can assume that in weight-bearing (Fig. 2), the source of the rotation is within the foot.

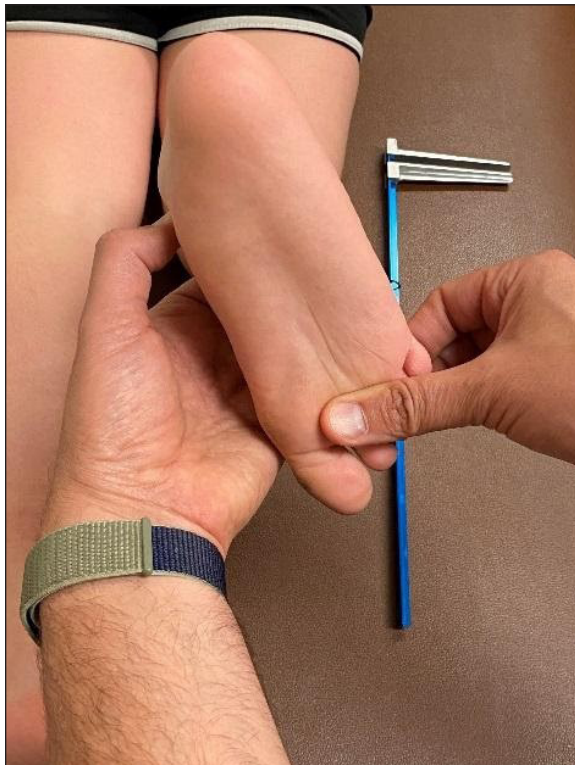

Fig. 1a. Foot thigh angle measured in simulated weight-bearing position, approximately 45 degrees external rotation.

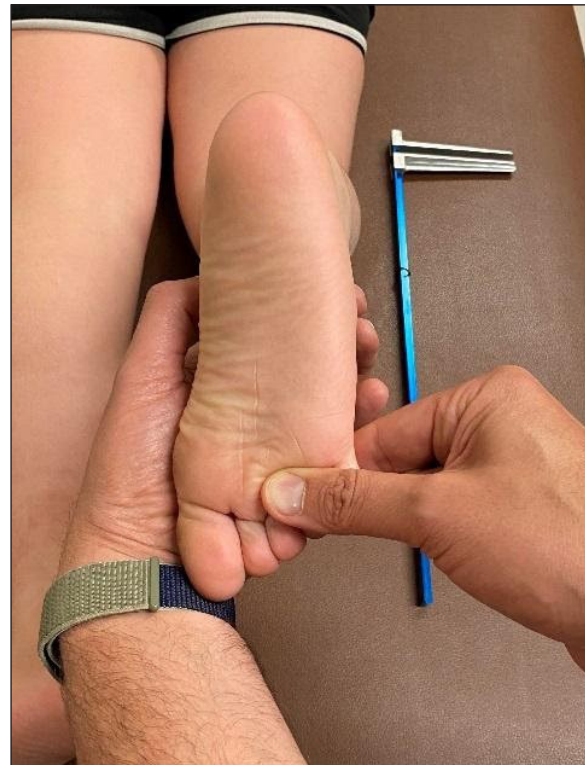

Fig. 1b. Foot thigh angle measured in subtalar neutral position. Approximately 0 degrees external rotation.

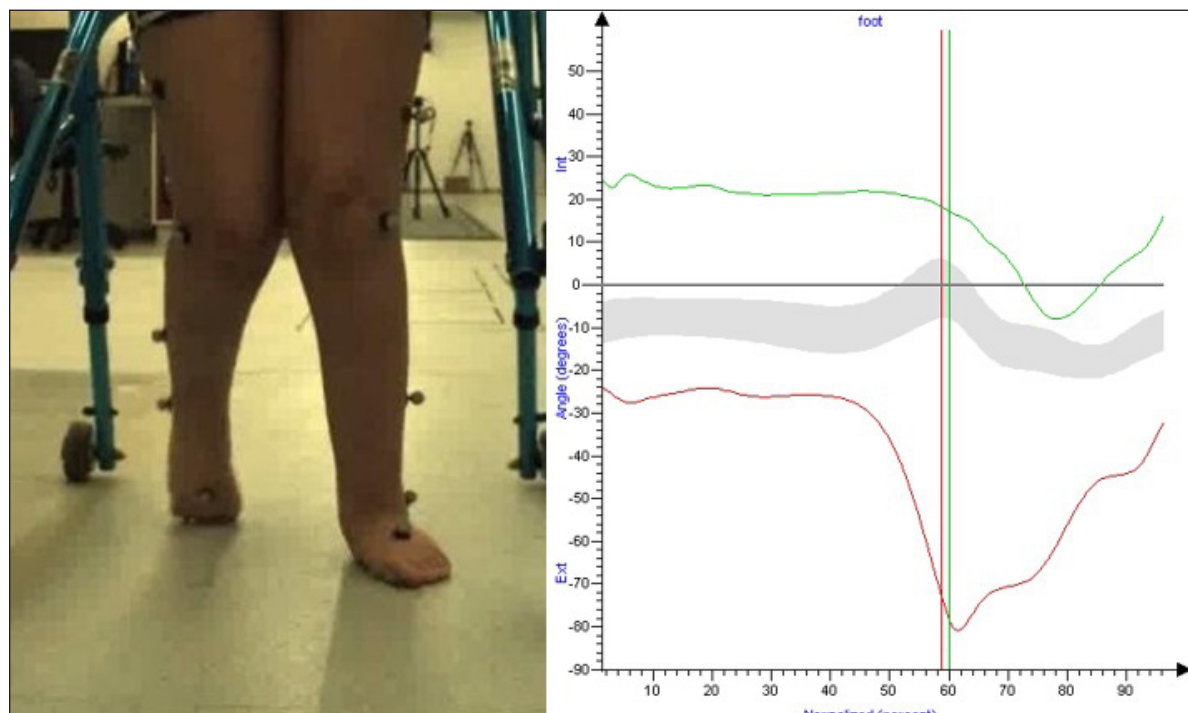


Fig. 2. External foot progression during walking – the left foot is in external foot progression throughout the stance phase, due to foot hyperpronation rather than external tibial torsion (left in red, right in green, norm in grey).

Discussion

TMA and TFA represent two clinical methods for evaluating tibial torsion. TFA is the more commonly employed method. This article emphasizes the significance of considering the subtalar joint during TFA measurements. Numerous studies have highlighted the impact of foot position on TFA (23, 17, 9, 18, 15, 24, 25), prompting the suggestion to term it the “Foot-Gotten Variable.” King and Staheli expressed a preference for TFA over TMA “when the foot is otherwise normal” (15). Staheli, Corbett, et al. advocated for obtaining both TFA and TMA in cases of “more complex torsional deformities”, especially those involving the foot, to facilitate a comparative analysis (22).

Stuberg, Temme, et al. defined TFA as a measurement encompassing both tibial torsion and “alignment distal to the talocrural joint” (19). Hudson emphasized the influence of “foot deformity, ankle instability, and knee instability” on TFA (17). Conversely, Kim, Lee, et al. identified

limitations in TFA validity compared to CT, particularly for “children with a deformed foot” (9). Kim, Cha et al. questioned the external validity of TFA findings by CT, asserting that such torsion measurements lack consideration of critical factors like “foot deformities” for surgical decision-making (21). Tamari and Tinley critiqued TFA as an inferior method due to its inclusion of “ankle and subtalar joint motions” in the outcome, challenging its suitability for measuring tibial torsion (25). A study involving 261 children with CP and out-toeing gait identified pes valgus as the most common cause of out-toeing (22). This emphasizes the need to consider foot dynamics in assessing rotational deformities.

Despite the mounting evidence against TFA (23, 9, 21, 18, 11), it persists as a common tool in clinical settings for assessing tibial torsion, inadvertently relegating the foot to a forgotten variable in the equation. A novel approach to TFA measurement involves assessing it in two different states: with the subtalar joint in a neutral position

and with the subtalar joint simulating a loaded or weight-bearing position. This innovative method may lead to more accurate diagnoses in the clinical setting, thereby enhancing clinical decision-making regarding treatment choices. Further research is necessary to investigate the correlation between rotational profile, foot rotation angle during gait, and TFA (both in STN and in a simulated weight-bearing position), among children presenting with rotational abnormalities. In particular, a randomized controlled trial comparing the efficacy of our novel assessment method to the traditional assessment method for measuring the rotational profile will enhance clinicians' utilization of evidence-based practice.

Author Contributions: SK: Conceptualization, Methodology, Investigation, Data Curation, Writing – Original Draft, Review & Editing, Supervision, Project Administration. BD: Writing – Review & Editing, Project Administration. BN: Conceptualization, Methodology, Writing – Original Draft, Review & Editing. RH: Conceptualization, Writing – Original Draft, Review & Editing. MA: Investigation, Data Curation, Writing – Original Draft, Review & Editing. All authors have read and agreed to the published version of the manuscript.

Conflict of Interest: The authors declare that they have no conflict of interest.

Ethical Considerations: This study, as a Clinical Commentary, is exempt from Institutional Review Board approval.

References

- Cooke TD, Price N, Fisher B, Hedden D. The inwardly pointing knee. An unrecognized problem of external rotational malalignment. *Clin Orthop Relat Res.* 1990;(260):56-60. PMID: 2225643.
- Eckhoff DG. Effect of limb malrotation on malalignment and osteoarthritis. *Orthop Clin North Am.* 1994;25(3):405-14. PMID: 8028884.
- Gose S, Sakai T, Murase T, Sugamoto K. Morphometric Analysis of the Femur in Cerebral Palsy: A 3-dimensional CT Study. *Journal of Pediatric Orthopedics.* 2010; 30(6):7. doi: 10.1097/BPO.0b013e3181e4f38d. PMID: 20733422.
- Robin J, Graham HK, Selber P, Dobson F, Smith K, Baker R. Proximal Femoral Geometry in Cerebral Palsy: A Population-Based Cross-Sectional Study. *The Journal of Bone and Joint Surgery-British Volume.* 2008;90-B(10):1372-9. doi: 10.1302/0301-620X.90B10.20733. PMID: 18827250.
- Cameron JC, Saha S. An Underrecognized Cause of Recurrent Patellar Dislocation. *Clinical Orthopaedics and Related Research.* 1996;328:8. PMID: 8653953.
- Schwartz M, Laki G. The Effect of Tibial Torsion on the Dynamic Function of the Soleus during Gait. *Gait & Posture.* 2003;17(2):113-8. PMID: 8653953.
- Turner MS. The Association Between Tibial Torsion and Knee Joint Pathology. *Clinical Orthopaedics and Related Research.* 1994;302:47-51. PMID: 8653953.
- Engel GM, Staheli LT. The Natural History of Torsion and Other Factors Influencing Gait in Childhood: A Study of the Angle of Gait, Tibial Torsion, Knee Angle, Hip Rotation, and Development of the Arch in Normal Children. *Clinical Orthopaedics and Related Research.* 1974;99:12-7. doi: 10.1097/00003086-197403000-00002. PMID: 4825705.
- Kim HD, Lee DS, Eom MJ, Hwang JS, Han NM, Jo GY. Relationship between Physical Examinations and Two-Dimensional Computed Tomographic Findings in Children with Intoeing Gait. *Annals of Rehabilitation Medicine.* 2011;35(4):491. doi: 10.1097/00003086-197403000-00002. PMID: 4825705.
- Massaad A, Assi A, Bakouny Z, Sauret C, Khalil N, Skalli W, et al. Three-dimensional Evaluation of Skeletal Deformities of the Pelvis and Lower Limbs in Ambulant Children with Cerebral Palsy. *Gait & Posture.* 2016;49:102-7. doi: 10.1097/00003086-197403000-00002. PMID: 4825705.
- Shih YC, Chau MM, Arendt EA, Novacheck TF. Measuring Lower Extremity Rotational Alignment: A Review of Methods and Case Studies of Clinical Applications. *Journal of Bone and Joint Surgery.* 2020;102(4):343-56. doi: 10.2106/JBJS.18.01115. PMID: 31743239.
- Rethlefsen SA, Healy BS, Wren TA, Skaggs DL, Kay RM. Causes of intoeing gait in children with cerebral palsy. *J Bone Joint Surg Am.* 2006u;88(10):2175-80. doi: 10.2106/JBJS.E.01280. PMID: 17015594
- Ruwe PA, Gage JR, Ozonoff MD, Deluca PA. Clinical Determination of Femoral Anteversion: A Comparison with Established Techniques. *The Journal of Bone & Joint Surgery.* 1992;74:820-30. PMID: 1634572.
- Uding A, Bloom NJ, Commean PK, Hillen TJ, Patterson JD, Clohisey JC, et al. Clinical Tests to Determine Femoral Version Category in People with Chronic Hip Joint Pain and Asymptomatic Controls. *Musculoskeletal Science and Practice.* 2019;39:115-22. doi: 10.1016/j.msksp.2018.12.003. PMID: 30553987; PMCID: PMC6353568.

15. King HA, Staheli LT. Torsional Problems in Cerebral Palsy. *Foot & Ankle*. 1984; 4(4):180-4. doi: 10.1177/107110078400400403. PMID: 6714858.
16. Cheng JC, Chan PS, Chiang SC, Hui PW. Angular and Rotational Profile of the Lower Limb in 2,630 Chinese Children. *Journal of Pediatric Orthopedics*. 1991;11(2):154-61. doi: 10.1097/01241398-199103000-00003. PMID: 2010512.
17. Hudson DA. Comparison of Ultrasound to Goniometric and Inclinator Measurements of Torsion in the Tibia and Femur. *Gait & Posture*. 2008;28(4):708-10. doi: 10.1016/j.gaitpost.2008.04.017. Epub 2008 Jun 13. PMID: 18555685.
18. Lee SH, Chung CY, Park MS, Choi IH, Cho TJ. Tibial Torsion in Cerebral Palsy: Validity and Reliability of Measurement. *Clinical Orthopaedics & Related Research*. 2009;467(8):2098-104. doi: 10.1007/s11999-009-0705-1. PMID: PMC2706340.
19. Stuberg W, Temme J, Kaplan P, Clarke A, Fuchs R. Measurement of tibial torsion and thigh-foot angle using goniometry and computed tomography. *Clin Orthop Relat Res*. 1991;(272):208-12. PMID: 1934735.
20. Luchini M, Stevens DB. Validity of Torsional Profile Examination. *Journal of Pediatric Orthopedics*. 1983;3(1):41-4. doi: 10.1097/01241398-198302000-00008. PMID: 6841602.
21. Kim HY, Cha YH, Chun YS, Shin HS. Correlation of the Torsion Values Measured by Rotational Profile, Kinematics, and CT Study in CP Patients. *Gait & Posture*. 2017;57:241-5. doi: 10.1016/j.gaitpost.2017.06.014. Epub 2017 Jun 22. PMID: 28668738.
22. Lattanza L, Gray GW, Kantner RM. Closed versus open kinematic chain measurements of subtalar joint eversion: implications for clinical practice. *J Orthop Sports Phys Ther*. 1988;9(9):310-4. doi: 10.2519/jospt.1988.9.9.310. PMID: 18796992.
23. Cao LA, Rethlefsen SA, Wren TAL, Kay RM. Causes of Out-toeing Gait in Children with Cerebral Palsy. *Gait & Posture*. 2020;76:141-45. doi: 10.1016/j.gaitpost.2019.12.002. PMID: 31855804.
24. Staheli LT, Corbett M, Wyss C, King H. Lower-extremity Rotational Problems in Children: Normal Values to Guide Management. *The Journal of Bone and Joint Surgery-American Volume*. 1985;67(1):39-47. PMID: 3968103.
25. Tamari K, Tinley P. A New Concept of Estimating Tibiofibular Torsion: An In Vivo Reliability Study. *Journal of Orthopaedic & Sports Physical Therapy*. 2003;33(2):85-90. doi: 10.2519/jospt.2003.33.2.85. PMID: 12619747.