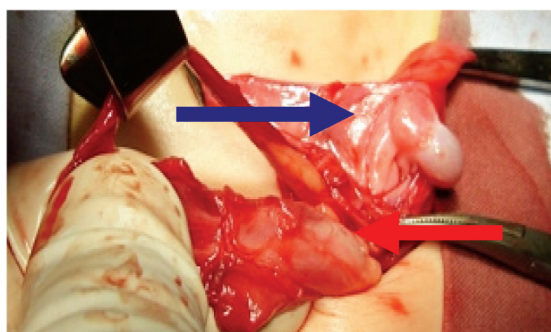


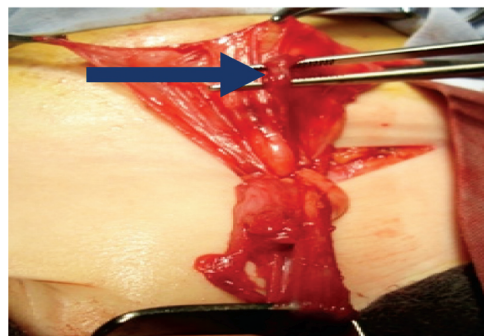
POLYORCHIDISM PRESENTING AS AN INGUINAL HERNIA

Edin HUSARIĆ, Nešad HOTIĆ, Amir HALILBAŠIĆ

Department of paediatrics, University clinical center Tuzla, Tuzla, Bosnia and Herzegovina
e-mail: ehusaric@hotmail.com; tel.: +387 35 303 369



Blue arrow supernumerary testis,
red arrows normal testis



Elements of the funiculus of
supernumerary testis (Blue arrow)

A 2-year-old boy was referred to the Outpatients' Department for Pediatric Surgery, at the Pediatric Clinic for a swelling in his left groin. The parents said that the swelling appeared a few months before and that it withdrew periodically, and that it had not yet incarcerated. On examination both testicles were normal in size, well placed in the scrotum, and the penis was of normal size and appearance. On the left it was a groin palpable minor swelling. The diagnosis was made of left inguinal hernia and surgery was indicated. During surgery the hernias sac was identified, and inside there was a formation reminiscent of a supernumerary testis (Figure A). Further exploration located anatomical structures corresponding to the vascular pedicle and ductus deferens of the supernumerary testis (Figure B). The above formation was resected and sent for histopathological diagnosis, and the hernia sac managed in the usual way. The histopathological report confirmed that it was immature testicular tissue with associated structures. Polyorchidism is an uncommon congenital anomaly, which implies the existence, proven histologically, of a supernumerary testis. Most often it is trioorchidism, and the supernumerary testis is usually on the left side. Polyorchidism is associated with undescended testes, groin hernia, testicular torsion and hydrocoele, and with malignancy and infertility. Because of the risk of malignant alteration it is recommended to remove the ectopic or atrophic supernumerary testis.