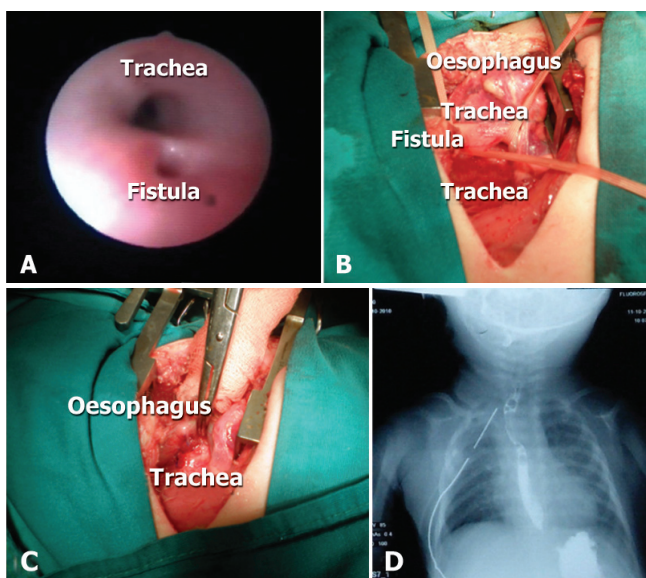


CONGENITAL „H“ TRACHEOESOPHAGEAL FISTULA OF NEWBORN*Dejan KAFKA, Maja MILIČKOVIĆ, Predrag MINIĆ, Vesna STEVANOVIĆ*

Mother and Children Health Institute of Serbia „dr Vukan Čupić“, Belgrade, Serbia

e-mail: kafka@vektor.net; tel.: + 381 11 310 8189; fax: + 381 11 319 5014

A mature female newborn contracted aspiration pneumonia during the first week of life. Due to progressive respiratory distress, the child was put on a regimen of mechanical ventilation. After every feeding, the milky secretion was aspirated from the tracheobronchial tree. After recovery, fiber optic tracheobronchoscopy was performed and an isolated tracheoesophageal fistula was discovered (Panel A). The child was admitted to the department of pediatric surgery. No associated anomaly was noted. On the seventeenth day of life, surgery was performed, starting with the repeated fiber optic tracheobronchoscopy. During this procedure, a plastic feeding tube was introduced through the tracheoesophageal fistula. The posterior mediastinum and the fistula were approached by the right posterolateral thoracotomy through the third intercostal space, with an extra pleural dissection. The fistula was isolated (Panel B), double ligation to both ends was performed and finally the fistula was resected (Panel C). The operation concluded with the drainage of the right hemithorax. On the seventh postoperative day, a barium radio-graphic essay of the esophagus was conducted, and the result was very satisfactory (Panel D). After that oral feeding was commenced and was event free. The child was discharged from hospital on the thirty-fifth day of life, in good general condition, with an increase in body mass, and without any therapeutic requirements. During the follow-up period, the clinical course was good. The radio-graphic barium essay of esophagus was repeated in the fifth month and was also good. An isolated tracheoesophageal fistula is a very rare anomaly in the spectrum of tracheoesophageal anomalies (4%). The fistula is usually manifested during the neonatal period by a cough, choking and aspiration pneumonia, which altogether lead to respiratory distress in the newborn. Clinical signs from the respiratory system associated with aspiration of gastric content from the tracheobronchial tree are an indication for performing fiber optic tracheobronchoscopy. This method is superior in diagnosis of tracheoesophageal fistulas. Treatment of tracheoesophageal fistulas is always surgical.

**Key words:** Tracheoesophageal fistula ■ Newborn

Copyright © 2011 by University Clinical Center Tuzla. E-mail for permission to publish: paediatricstoday@ukctuzla.ba

Citation: Kafka D, Miličković M, Minić P, Stevanović V. Congenital „H“ tracheoesophageal fistula of newborn. Paediatrics Today. 2011;7(2):150.