

## SONOGRAPHY OF THE ACUTE SCROTUM IN CHILDREN

Goran ROIĆ\*

Children's Hospital Zagreb, Department  
of Pediatric Radiology, Zagreb, Croatia

\*Corresponding author:

*goran.roic@kdb.hr*

Tel.: + 385 1 46 02 74

Fax.: + 385 1 460 01 13

**Received:** November 21, 2015

**Accepted:** January 18, 2016

**Key words:** Ultrasonography ■ Acute  
scrotum ■ Children.

This review aims to describe the various ultrasonographic appearances of the most common acute scrotal disorders in children. Ultrasonography (US) is the primary imaging modality for evaluating the acute scrotum in children, especially when the history and physical examination do not adequately explain acute scrotal swelling and pain in a child. The acute scrotum is defined as the sudden onset of scrotal pain accompanied by swelling, redness or discoloration. By understanding and recognizing the US appearances of acute pediatric scrotal disorders, the ultrasonographer can make a very significant contribution to the care of these patients, guiding the clinician toward appropriate therapy. **Conclusion** – US provides excellent anatomic details and permits differentiation between lesions that require urgent surgery and scrotal exploration and those that can be managed conservatively.

### Introduction

Ultrasonography, in combination with color or power Doppler imaging, is the imaging modality of choice for the evaluation of acute scrotal disorders in children, especially when the history and physical examination do not adequately explain scrotal swelling (1, 2, 3, 4, 5). It is widely available to provide rapid and timely assessment without radiation risk to children. When combined with the results of clinical and physical examination, the information obtained with US is sufficient to enable diagnosis of acute pediatric scrotal disease in most cases, guiding the clinician toward the appropriate therapy. US combined with color or power Doppler provides excellent anatomical details and assessment of testicular perfusion without ionizing radiation, and many scrotal diseases can be characterized, differentiating lesions requiring urgent surgery from those that can be managed conservatively. Clinical manifestations in

acute scrotal processes include pain, swelling, redness and a palpable mass. US provides excellent anatomic detail and permits differentiation between lesions requiring urgent surgery and scrotal exploration (*testicular torsion, traumatic rupture*) and those that can be managed conservatively (*e.g. torsion of the testicular appendages, epididymo-orchitis*) (6). Thorough knowledge of typical ultrasonographic findings of these disorders is necessary in giving accurate diagnoses in order to perform appropriate therapy. By identifying the site of origin in a variety of acute scrotal abnormalities, the diagnosis is usually readily made, making ultrasonography especially valuable in patient management.

The term “*acute scrotum*” is defined as a sudden-onset of scrotal swelling and pain and is a common cause of visits to the emergency department among boys. The common causes include testicular appendageal torsion, epididymo-orchitis, and testicular torsion

(7, 8). Acute scrotal swelling can also occur due to testicular or scrotal injury. Testicular torsion is the most important diagnosis to rule out because it is a surgical emergency. A correct diagnosis can help avoid unnecessary surgical interventions, and characteristic ultrasonographic and Doppler findings can be imperative given the overlap in clinical presentation with testicular torsion and other conditions.

Scrotal US is performed with the patient lying in a supine position and with the scrotum supported by a towel placed between the thighs. Warm gel is used to minimize pressure on the scrotum (1). The use of a 7–15 MHz high-frequency linear-array transducer is essential. After a trauma, the scrotum is often tender to a touch, which makes scanning difficult. An attempt should be made to evaluate both testicles and epididymides in their entirety and to identify any extratesticular collections. The testicles are evaluated in longitudinal and transverse planes. Since acute scrotal disorders are usually unilateral, we start the ultrasonographic examination on the asymptomatic side to determine the basis for comparison. Color Doppler imaging, adjusted to visualize low flow velocities, or power Doppler imaging should always be added to the gray-scale study. Pulsed-wave Doppler imaging is not absolutely necessary. Comparable transverse Doppler scans of both testicles are extremely important to study testicular gray-scale and perfusion discrepancies (1). This review describes the typical ultrasonographic features of the most common acute scrotal disorders in children.

Contrast-enhanced ultrasound (CEUS) is a new technique that improves the depiction of parenchymal disorders on the base of vascularity, can be used to unequivocally demonstrate perfusion and viability of testis. Potential applications in acute scrotal diseases range from distinction of acute epididymitis/orchitis from testicular torsion, segmental testicular infarction from testicular tumor,

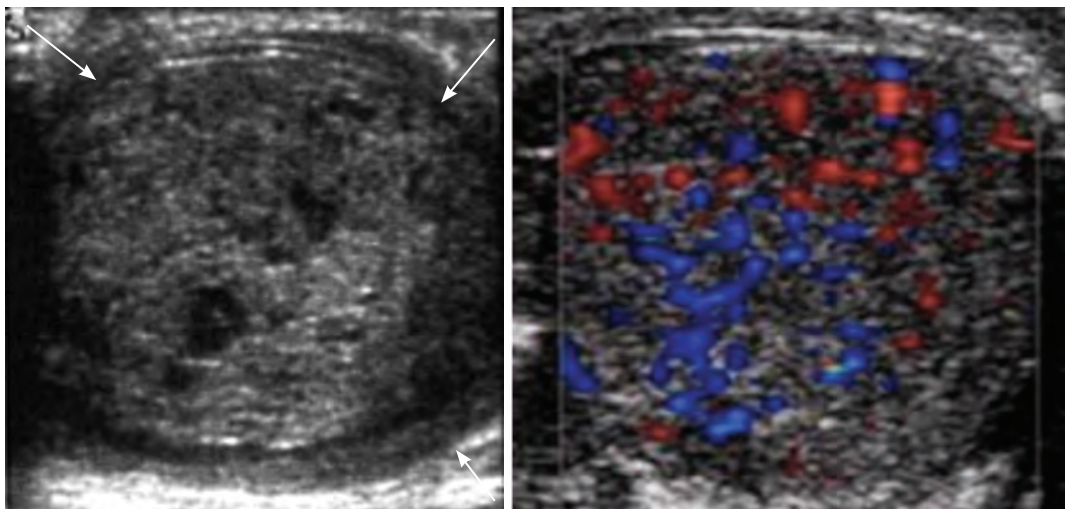
and quantitative assessment of viable parenchyma in scrotal trauma. CEUS is currently used in adults but could potentially be considered for children as well, in inconclusive cases (9).

### **Testicular torsion**

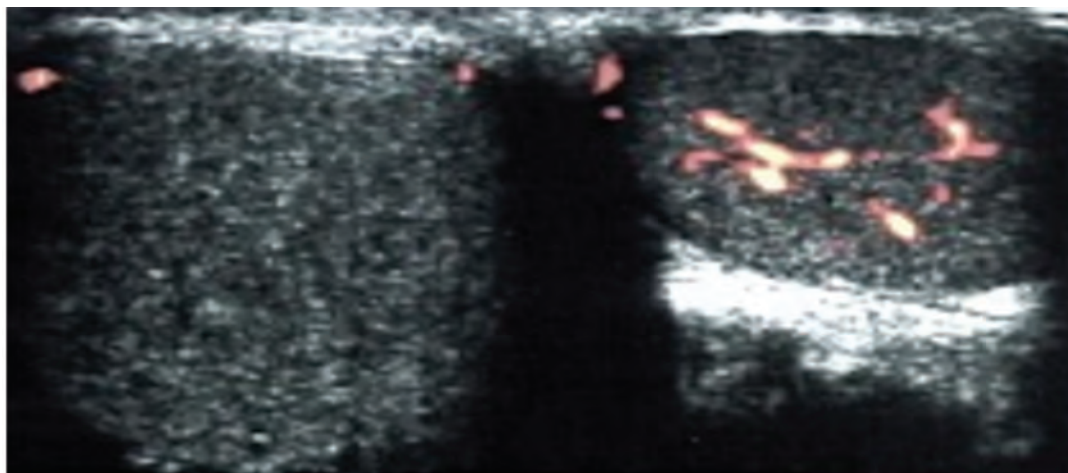
Testicular torsion, or twisting of the spermatic cord, implies first venous and later arterial flow obstruction. The extent of testicular ischemia will depend on the degree of twisting (180°–720°) and the duration of the torsion. Incomplete torsion refers to cord twisting of less than 360°, in which some arterial flow persists in the affected testicle. Because of the disruption of testicular blood supply in torsion, time is a crucial factor in salvaging the affected testicle. The salvage rate can be up to 80–100% in patients with a surgery within 4–6 hours after the onset of torsion, and less than 20% with a surgery after 12 hours (10). Patients usually present with an acute onset of diffuse scrotal pain, nausea and vomiting. Physical findings can include high-riding testicle and absent cremasteric reflex.

Testicular torsion is primarily a disease of adolescents and neonates. There are two types of testicular torsion: extravaginal and intravaginal. Extravaginal torsion is seen mainly in newborns and in most cases occurs prenatally (11). The testicle is usually necrotic at birth and the hemiscrotum is swollen and discolored (Fig. 1). US findings vary, but complex hydrocele and calcification of the tunica albuginea are common. Intravaginal torsion can occur at any age but is more common in adolescents. A predisposing factor is the “*bell clapper*” deformity, in which the tunica vaginalis joins high on the spermatic cord, leaving the testicle free to rotate.

In the early phases of torsion (1–3 hours), testicular echogenicity appears normal. With progression, enlargement of the affected testicle and increased or heterogeneous echogenicity are common findings (Fig. 2). Ultrasono-



**Fig. 1** Transverse US of the scrotum in a newborn with a firm discolored right hemiscrotum shows a heterogeneous right testicle surrounded by thickened tunica albuginea (white arrows) and scrotal soft tissues; No Doppler flow was demonstrable; Extravaginal testicular torsion. Normal blood flow to the left testicle.



**Fig. 2** US of the scrotum - longitudinal and transverse images demonstrate enlargement of the (right) testicle with heterogeneous avascular structure, consistent with a torsed testicle. Power Doppler - No flow. The right testis was infarcted at the time of surgery and was removed.

graphic evaluation of the spermatic cord is an essential part of the examination. The point of cord twisting can be identified at the external inguinal orifice. The intrascrotal portion of the edematous cord appears as a round, ovoid, or curled echogenic extratesticular mass, with the epididymal head wrapped around it. (12). A definitive diagnosis of complete testicular torsion is made when blood flow is visualized on the normal side but is absent or reduced on

the affected side (7, 12). Comparison of the two testicles by using transverse and longitudinal views is mandatory.

Differentiation between testicular torsion and epididymo-orchitis is a clinical challenge, since scrotal pain, swelling and redness or tenderness are clinical symptoms common to these two entities. The usual rule is that the pain in testicular torsion has a sudden onset, whereas in orchitis it is more gradual.

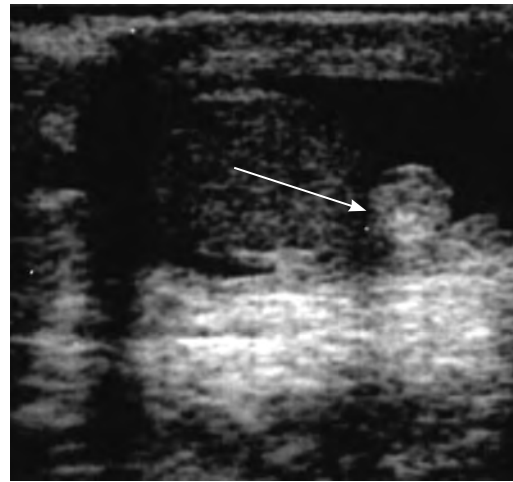
However, about 5% of children with orchitis have a sudden onset of pain, and only 50% of patients with testicular torsion have an acute attack (13).

### Torsion of the testicular appendages

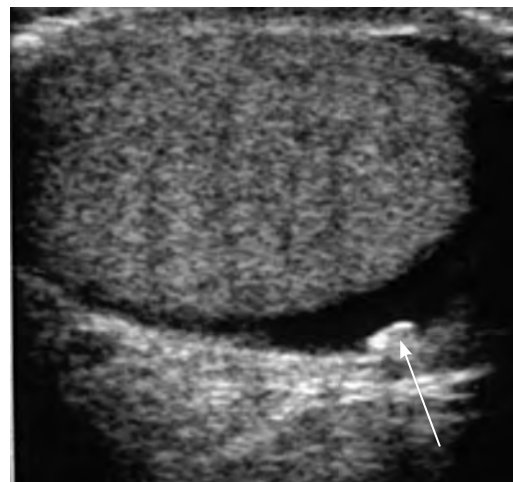The testicular appendages are normal remnants of the embryonic mesonephric and paramesonephric ducts, usually located at the superior testicle or epididymal head. The appendages are most often sessile structures but could have varying morphologic characteristics predisposing them to torsion (14). Testicular appendages are more frequent than epididymal appendages. Distinction is often difficult to make but it is not clinically important (15). Torsion of the appendix testicle occurs mainly in pre-pubertal boys (aged 6-12 years), is more frequent on the left side, and is a common cause of acute scrotum in this age group (1, 16, 17). Affected patients typically experience gradual or sudden intense pain, usually localized in the upper pole of the testicle. These boys are less likely to have nausea and vomit than boys with testicular torsion. In approximately one third of patients, a nodule of the upper scrotum with bluish skin discoloration (*"blue dot" sign*) is palpated (18, 19). This is a highly specific finding of this entity.

Sonographically, the twisted appendage is seen as a round extratesticular mass with high or mixed echogenicity depending on the evolution time (20) (Fig. 3). The torted appendage becomes more echogenic with time. Associated findings include an enlarged epididymal head, reactive hydrocele and scrotal skin thickening. There is no Doppler signal in the twisted appendage, and the epididymis and scrotal tunic are hypervascularised. Increased vascularity in the epididymis and testicle may mimic epididymitis or orchitis. Additional findings include secondary inflammatory changes, including enlargement of the epididymal head, reactive hydrocele and scrotal

skin thickening and swelling (21). The epididymis and scrotal wall may be hypervascularised, while no blood flow can be seen in the twisted appendage (1). Within days, the twisted appendix may calcify and become detached, leaving scrotal calcification, known as a scrotolith (Fig. 4) (14). Treatment typically involves conservative management (13).



**Fig. 3** Gray-scale US image in a 9-year-old boy with scrotal pain, erythema and enlarged right hemiscrotum shows well-defined hyperechoic nodule at upper pole of right testis consistent with a torted appendage (arrow); Reactive hydrocele. No detectable flow on color and power Doppler.



**Fig. 4** US image in a patient with a prior history of a torted appendage shows a calcification freely mobile within the scrotum – Scrotolith (arrow).

## Epididymo-orchitis

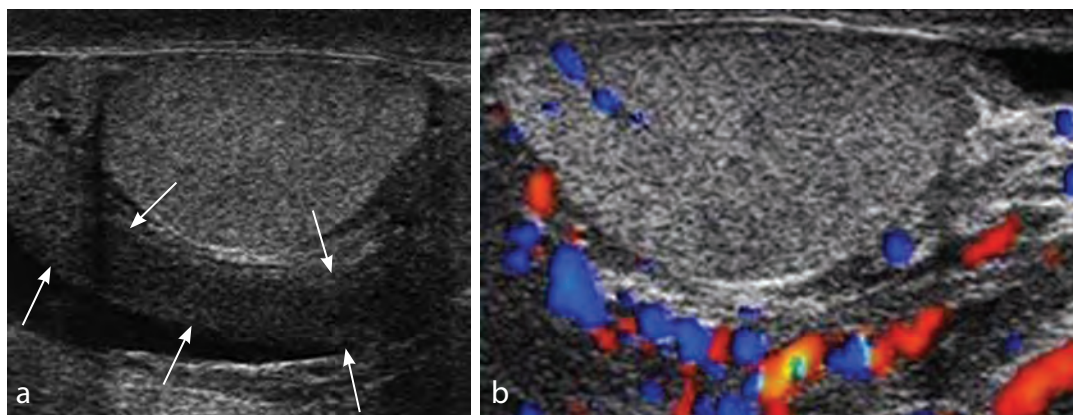
Epididymo-orchitis, which is mainly of infectious origin, is a common cause of acute scrotum in children, accounting for up to 21% of cases (7, 14). In post-pubertal male patients it is usually related to retrograde extension of infection spreads from the bladder or prostate gland, through the vas deferens and the lymphatics of the spermatic cord to the epididymis, and eventually reaches the testicle, causing epididymo-orchitis (20-40%) (22, 23). In pre-pubertal boys epididymo-orchitis is mostly idiopathic, but can be related to underlying urogenital anomalies (24). Predisposing factor includes imperforate anus, ureteral ectopia to the seminal vesicle, bladder exstrophy, neurogenic bladder, posterior urethral valves, and dysfunctional voiding, particularly in patients under 2 years of age (25). There are two peaks of prevalence: under 2 years of age and over 6 years of age. Mumps orchitis occurs in approximately 30% of infected post-pubertal boys (26). The epididymal head is the most affected region, but occasionally the entire epididymis is affected. Primary isolated orchitis is less common than secondary epididymo-orchitis and is usually viral in origin. The clinical spectrum ranges from mild tenderness to a severe febrile pro-

cess (3, 15). Patients typically present with a gradual onset of scrotal pain with fever.

Sonographically, there is enlarged hyperechoic epididymis with scrotal wall swelling and a reactive hydrocele (Fig. 5). The epididymal head is the most affected, but occasionally the entire gland can be affected (7). Depending on the time of evolution, decreased, increased, or heterogeneous echogenicity of the affected epididymis are usually observed. Around 20% cases are complicated by orchitis (21). The inflammation produces increased blood flow within the epididymis, the testicle, or both. In a few cases showing clinical symptoms of epididymitis with normal echogenicity, increased blood flow allows the diagnosis to be established (3, 27). Analysis of the epididymal waveform may reveal a low-resistance pattern as compared to the normal pattern (28). Complications include abscess, pyocele, and focal infarction.

Malignancies such as leukemia and lymphoma that diffusely infiltrate the testicular parenchyma, may have a US appearance similar to that of diffuse orchitis. The clinical history is extremely important for the differential diagnosis (7).

Granulomatous epididymo-orchitis is a chronic inflammation occurring in post-pu-

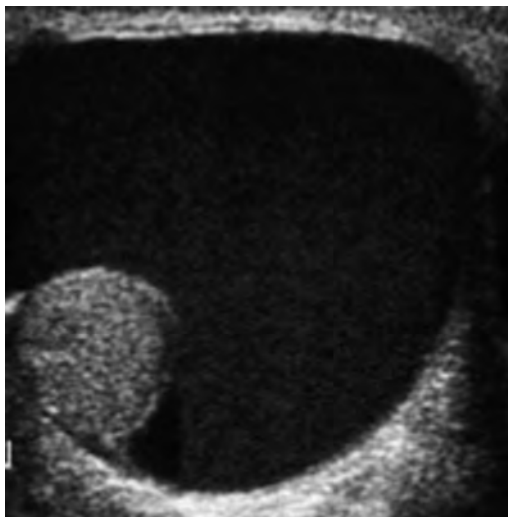


**Fig. 5** a) Longitudinal grayscale sonogram in a 10-year-old boy with scrotal pain and redness shows an enlarged and hyperechoic epididymis (white arrows) with reactive hydrocele; Epididymitis. b) Colour Doppler increased vascularity within the inflamed epididymis.

bertal boys and consists of a granulomatous reaction to sperm or some microorganisms. The affected part of the epididymis, mainly the tail, is enlarged with heterogeneous echogenicity (29). At color Doppler imaging chronic epididymo-orchitis does not demonstrate an increased blood flow typical of acute epididymitis. The ultrasonographic appearance can be similar to those of epididymal adenomatoid tumor; however, patients with chronic epididymitis present with a painful mass, whereas the tumor is usually painless (7).

### Testicular trauma

Despite the vulnerable position of the testicles, traumatic testicular injuries are relatively uncommon because the testicles are protected by mobility within the scrotum, laxity of the overlying skin and coverage by the tunica albuginea (29, 30). Haematocele is the most common finding following trauma, which initially appears echogenic and becoming hypoechoic as it evolves (Fig. 6). Testicular trauma is the third most-common cause of acute scrotal pain and may result in various degrees of damage to the testicles. Scrotal trauma in boys is most commonly due to sports-related

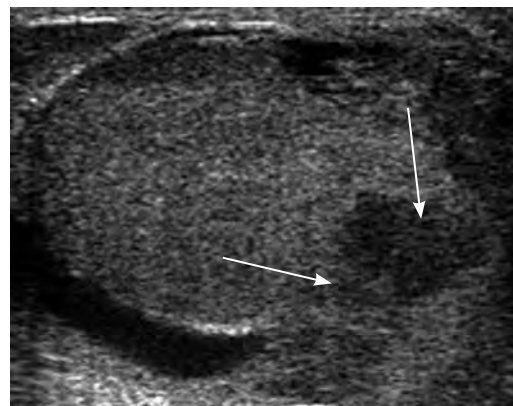


**Fig. 6** US of the scrotum acute haematocele: Hypoechoic intrascrotal collection.

activities (> 50%), followed by motor vehicle accidents (17%) (15, 29). Ultrasonography is the first-line imaging for the assessment of scrotal trauma. It is ideal for non-invasive evaluation of the scrotal contents, testicular integrity and blood flow, as well as to visualize hematomas or other fluid collections.

### Testicular rupture

Testicular rupture involves disruption of the tunica albuginea, with extrusion of testicular contents, and haematocele is usually present. This can lead to the loss of a normal oval shape of the testicle. Ultrasonography shows a heterogeneous testicle with irregular contours and a disrupted tunica albuginea (30, 31) (Fig. 7). In the setting of trauma, accurately diagnosing testicular rupture is immensely important since treatment involves urgent surgical exploration with debridement and closure of the tunica albuginea if necessary (16, 30).



**Fig. 7** US of the scrotum in a 14-year-old boy within 8 hours after scrotal injury - tunica albuginea can no longer be seen, inhomogeneous prolapsing testicular tissue (white arrows); Testicular rupture.

### Testicular fracture

Testicular fracture involves a break or discontinuity within the normal testicular pa-

renchyma. However, the tunica albuginea remains intact, and thus the testicle maintains its normal shape. Ultrasonography shows a linear hypoechoic “*fracture line*” within the normally shaped testicle (29, 30). Treatment is usually non-surgical, conservative management.

### Testicular hematoma

Testicular hematomas may be intratesticular or extratesticular. Ultrasonography usually shows avascular heterogeneous complex collections within or outside the testicle, corresponding to the hematoma (15, 30, 31). Treatment of small hematomas is usually conservative; however, large hematomas may require surgical intervention to evacuate hematoma and prevent pressure necrosis and testicular atrophy (30).

### Other causes of scrotal swelling

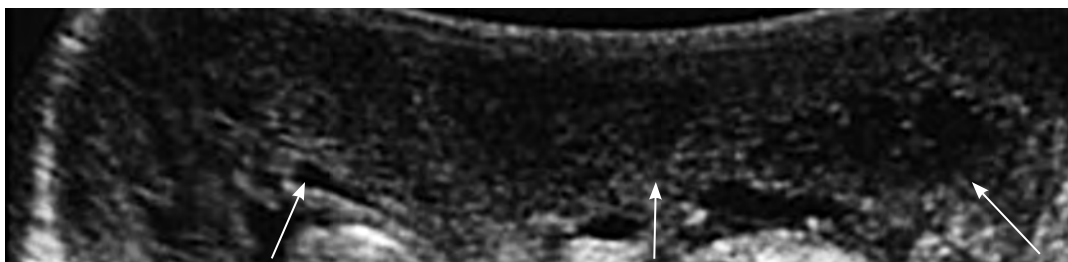Acute idiopathic scrotal edema is a rare disorder that can cause acute scrotal swelling and erythema in boys and is usually painless. Its exact cause is unclear, but it may have an allergic origin (32). Ultrasonography and color Doppler show diffuse scrotal edema and hyperemia (3) (Fig. 8). Geiger has described the “*fountain sign*,” a novel finding on colour Doppler which is highly suggestive of the diagnosis. The “*fountain*” depicted on transverse imaging of the scrotum is due to increased hypervascularity in the scrotal wall

which derives its blood supply from branches of the deep external pudendal and internal pudendal arteries via the anterior and posterior sacral arteries (33). Acute idiopathic scrotal edema is self-limited and treatment is conservative, with a tendency to resolve in around 3-5 days.

Another cause of acute scrotal pain and swelling in pediatric age is Henoch-Schönlein purpura. Henoch-Schönlein purpura is a systemic vasculitis more commonly seen in children; it usually affects the skin, kidneys, gastrointestinal tract and joints. Scrotal involvement is rare but can occur in up to 15-37% of cases (34, 35). Ultrasonographic findings typically include thickening of the scrotal skin, enlargement of the epididymis, and presence of hydrocele (7). In Henoch-Schönlein purpura, the testicles are usually unaffected and normal testicular blood flow is maintained.

### Conclusion

As the different pathologies can have similar presentations, clinical evaluation of acute pediatric scrotal pathologies can be challenging. Scrotal tenderness, edema and pain may limit physical examination. Ultrasonography is the imaging modality of choice for acute pediatric scrotum. It is widely available and provides excellent anatomical detail and assessment of testicular perfusion by color Doppler without using of ionizing radiation. In pediatric acute scrotum, US can differentiate between tes-



**Fig. 8** US of the scrotum in a 5-year-old boy with acute painless scrotal swelling and erythema shows thickened and edematous hypoechoic scrotal wall (white arrows); Acute idiopathic scrotal edema.

ticular torsion requiring scrotal exploration and other acute pathologies with conservative management. This article reviews scrotal US anatomy and demonstrates that US can guide management in a variety of acute scrotal abnormalities including testicular torsion, torsion of testicular appendages, epididymo-orchitis, testicular trauma and some other causes of acute scrotal swelling.

**Conflict of interest:** The author declares that he has no conflict of interest.

## References

- Howlett DC, Marchbank ND, Sallomi DF. Ultrasound of the testis. *Clin Radiol*. 2000;55:595-601.
- Munden MM, Trautwein LM. Scrotal pathology in pediatrics with sonographic imaging. *Curr Probl Diagn Radiol*. 2000;29:185-205.
- Coley BD, Siegel MJ, ed. *Pediatric sonography*. 3rd ed. Philadelphia, Lippincott Williams & Wilkins, 2002;579-624.
- Frush DP, Sheldon CA. Diagnostic imaging for pediatric scrotal disorders. *RadioGraphics*. 1998;18:969-85.
- Dogra VS, Gottlieb RH, Oka M, Rubens DJ. Sonography of the scrotum. *Radiology*. 2003;227:18-36.
- Kass EJ, Lundak B. The acute scrotum. *Pediatr Clin North Am*. 1997;44:1251-266.
- Enriquez G, Fite M, Toran N, Piro C, Piqueras J, Lucaya J. Gray-Scale and Color Doppler Sonography of Scrotal Disorders in Children: An Update. *RadioGraphics*. 2005;25:1197-214.
- Baldisserotto M. Scrotal emergencies. *Pediatr Radiol*. 2009;39:516-21.
- Valentino M, Bertolotto M, Derchi L, Bertaccini A, Pavlica P, Martorana G, et al. Role of contrast enhanced ultrasound in acute scrotal diseases. *Eur Radiol*. 2011;21(9):1831-40.
- Prando D. Torsion of the spermatic cord: the main gray-scale and Doppler sonographic signs. *Abdom Imaging*. 2009;34:648-61.
- Brown SM, Casillas VJ, Montalvo BM, Albores-Saavedra J. Intrauterine spermatic cord torsion in the newborn: sonographic and pathologic correlation. *Radiology* 1990;177:755-7.
- Chmelnik M, Schenk JP, Hinz U, Holland-Cunz S, Gunther P. Testicular torsion: sonomorphological appearance as a predictor for testicular viability and outcome in neonates and children. *Pediatr Surg Int*. 2010;26:281-86.
- Leape LL. Torsion of the testis: invitation to error. *JAMA*. 1967;200:669-72.
- Rafailidis V, Apostolou D, Charsoula A, Rafailidis D. Sonography of the scrotum: from appendages to scrotolithiasis. *J Ultrasound Med*. 2015;34(3):507-18.
- Sung EK, Setty BN, Castro-Aragon I. Sonography of the Pediatric Scrotum: Emphasis on the Ts - Torsion, Trauma, and Tumors. *American Journal of Roentgenology*. 2012;198:996-1003.
- Monga M, Scarpero HM, Ortenberg J. Metachronous bilateral torsion of the testicular appendices. *Int J Urol*. 1999;6:589-91.
- Baldisserotto M, Ketzer de Souza JC, Pertence AP, Dora MD. Color Doppler sonography of normal and torsed testicular appendages in children. *AJR*. 2005;184:1287-92.
- Schmitz D, Safranek S. Clinical inquiries. How useful is a physical exam in diagnosing testicular torsion?. *J Fam Pract*. 2009;58(8):433-4.
- Nason GJ, Tareen F, McLoughlin D, McDowell D, Cianci F, Mortell A. Scrotal exploration for acute scrotal pain: a 10-year experience in two tertiary referral paediatric units. *Scand J Urol*. 2013;47(5):418-22.
- Hesser U, Rosenborg M, Gierup J, Karpe B, Nyström A, Hedenborg L. Gray-scale sonography in torsion of the testicular appendages. *Pediatr Radiol*. 1993;23:529-32.
- Singh AK, Kao SC. Torsion of testicular appendage. *Pediatr Radiol*. 2010;40:373.
- Kim W, Rosen MA, Langer JE, Banner MP, Siegelman ES, Ramchandani P. US-MR imaging correlation in pathologic conditions of the scrotum. *RadioGraphics*. 2007; 27:1239-53.
- Gronski M, Hollman AS. The acute paediatric scrotum: the role of colour Doppler ultrasound. *Eur J Radiol*. 1998;26:183-93.
- Karmazyn B, Kaefer M, Kauffman S, Jennings SG. Ultrasonography and clinical findings in children with epididymitis, with and without associated lower urinary tract abnormalities. *Pediatr Radiol*. 2009;39:1054-58.
- Hudnall TW, Meservy C. Vas deferens ectopia: an uncommon finding. *Pediatr Radiol*. 2004;34:179.



26. Kogan S, Hadziselimovic F, Howards SS. Pediatric andrology. In: Gillenwater JY, Grayhack JT, Howards SS, Duckett JW, editors. Adult and pediatric urology. 3rd edition. St. Louis: Mosby; 1996. p. 2623-74.
27. Stengel JW, Remer EM. Sonography of the scrotum: Case-based review. *AJR Am J Roentgenol.* 2008;190:S35-S41.
28. Horstman WG, Middleton WD, Melson GL. Scrotal inflammatory disease: color Doppler US findings. *Radiology.* 1991;179:55-9.
29. Salmeron I, Ramirez-Escobar M, Puertas F, Marcos R, Garcia-Marcos F, Sanchez R. Granulomatous epididymo-orchitis: sonographic features and clinical outcome in brucellosis, tuberculosis and idiopathic granulomatous epididymo-orchitis. *J Urol.* 1998;159:1954-7.
30. Bhatt S, Dogra VS. Role of US in testicular and scrotal trauma. *RadioGraphics.* 2008;28:1617-629.
31. Deurdulian C, Mittelstaedt CA, Chong WK, Fielding JR. US of acute scrotal trauma: optimal technique, imaging findings, and management. *RadioGraphics.* 2007;27:357-69.
32. Klin B, Lotan G, Efrati Y, Zlotkevich L, Strauss S. Acute idiopathic scrotal edema in children: revisited. *J Pediatr Surg.* 2002;37:1200-2.
33. Geiger J, Epelman M, Darge K. J. The fountain sign: a novel color Doppler sonographic finding for the diagnosis of acute idiopathic scrotal edema. *Ultrasound Med.* 2010;29(8):1233-7.
34. Ben-Sira L, Laor T. Severe scrotal pain in boys with Henoch-Schonlein purpura: incidence and sonography. *Pediatr Radiol.* 2000;30:125-28.
35. Laor T, Atala A, Teele RL. Scrotal ultrasonography in Henoch-Schonlein purpura. *Pediatr Radiol.* 1992;22:505-6.