

## Twisting of a Giant Cystic Meckel's Diverticulum in a Toddler: A Case Report and Brief Literature Review

Zlatan Zvizdic<sup>1</sup>, Asmir Jonuzi<sup>1</sup>, Irmina Sefic Pasic<sup>2</sup>, Semir Vranic<sup>3,4</sup>

<sup>1</sup>Clinic of Pediatric Surgery, University Clinical Center Sarajevo, Sarajevo, Bosnia and Herzegovina, <sup>2</sup>Department of Radiology, University Clinical Center Sarajevo, Sarajevo, Bosnia and Herzegovina, <sup>3</sup>College of Medicine, QU Health, Qatar University, Doha, Qatar, <sup>4</sup>Biomedical and Pharmaceutical Research Unit, QU Health, Qatar University, Doha, Qatar

**Correspondence:** [semir.vranic@gmail.com](mailto:semir.vranic@gmail.com) or [svranic@qu.edu.qa](mailto:svranic@qu.edu.qa); Tel.: + 974 4403 7873 Fax.: + 974 4403 7800

**Received:** July 8, 2021; **Accepted:** July 31, 2021

### Abstract

**Objective:** Herein we report an unusual case of torsed giant cystic Meckel's diverticulum (MD) in a three-year-old boy, illustrating the rarity of this condition and briefly reviewing the literature on it. **Case Report:** A three-year-old boy who clinically presented with severe colicky abdominal pain and frequent vomiting. Abdominal ultrasonography showed a cystic lesion in the lower abdomen. Contrast-enhanced CT revealed a well-defined right upper quadrant cystic mass measuring  $\sim 5 \times 4$  cm. The cystic mass appeared to be arising from the small intestine. The radiological features were not suggestive of malignancy. An urgent laparotomy was performed. At operation, he was found to have an incomplete torsed giant cystic MD. Postoperative recovery was uneventful, and the patient was discharged on the sixth postoperative day. A regular, 3-year follow-up revealed no complications. **Conclusion:** A giant cystic Meckel's diverticulum represents a rare cause of intra-abdominal/pelvic mass and should be considered in its differential diagnosis. Timely surgical intervention reduces morbidity and provides the best clinical outcome.

**Key Words:** Meckel's diverticulum ■ Intra-abdominal cystic lesions ■ Torsion ■ Children.

### Introduction

Meckel's diverticulum (MD), an embryonic remnant of the omphalomesenteric duct, is one of the most common intestinal congenital malformations found in 0.14 % to 4.5% of cadaver dissections (1). It was first described by Fabricius Hildanus in 1598 as an "unusual diverticulum" of the small intestine, but Johann Friedrich Meckel's first correctly recognized its embryologic origin in 1809 (2).

MD usually stays asymptomatic during a lifetime, and most cases are discovered incidentally during surgery or radiologic exam. However, if a MD does become symptomatic, its common presentations in children include various intestinal

obstructions caused by intussusception, volvulus or mesodiverticular bands, gastrointestinal bleeding, and diverticulitis (3). The lifetime risk of diverticulum complications is 4% to 6%, and approximately 40% of these complications are seen in children below the age of ten (4). Due to a highly variable clinical presentation, it may be challenging to differentiate symptomatic MD from other acute abdominal diseases. Although uncommonly encountered, MD may present as a cystic or complicated abdominal/pelvic mass (5).

Herein we report an unusual case of torsed giant cystic MD in a three-year-old boy, illustrating the rarity of this condition.

## Case Report

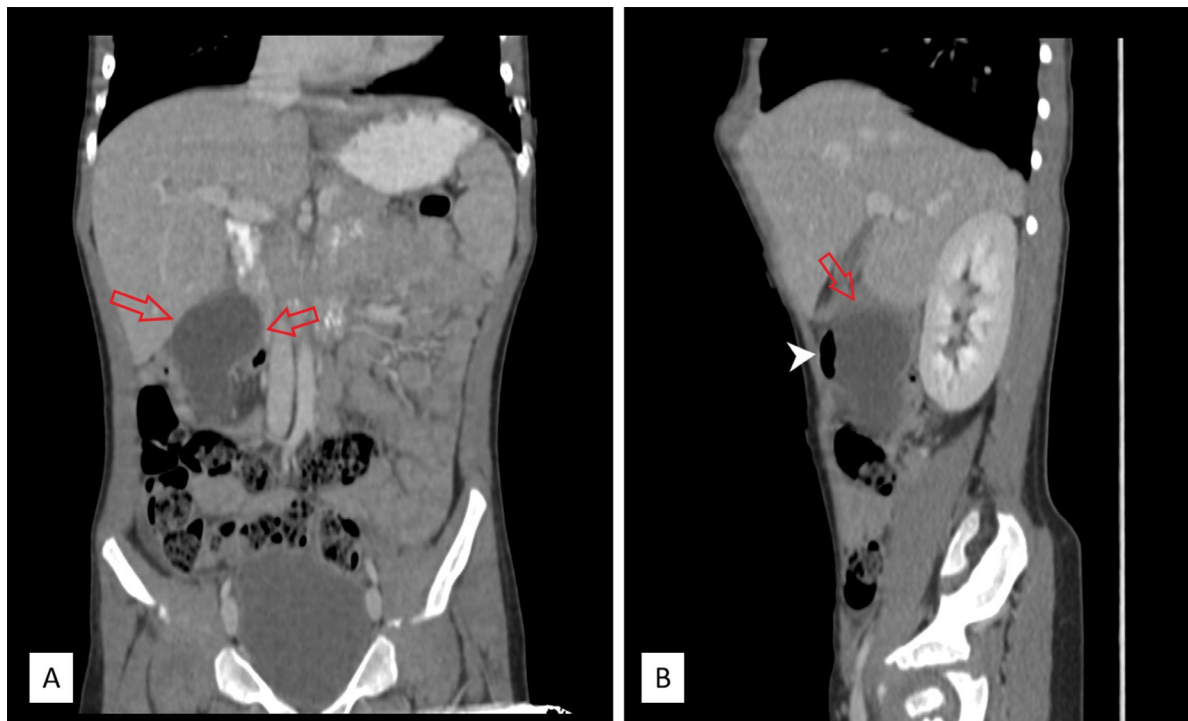
A 3-year-old boy was admitted to the pediatric emergency department for a 9-hour history of severe colicky abdominal pain and several episodes of bilious vomiting. The patient was afebrile and hemodynamically stable with unremarkable laboratory results, including a normal white blood cell count ( $10.5 \times 10^3/\text{mL}$ ) and C-reactive protein (2.1 mg/dL). On physical examination, abdominal guarding and rebound tenderness was present in his paraumbilical area. A mass that was approximately 5 cm in diameter was also palpated at the middle abdomen. Abdominal ultrasonography showed a cystic lesion in the lower abdomen. The appendix was normal. Contrast-enhanced computed tomography (CT) revealed a well-defined right upper quadrant cystic mass measuring  $3.9 \times 3.6 \times 4.7$  cm (Fig. 1A-B). The cystic mass appeared to be arising from the small intestine. There were no radiological features suggestive of malignancy.

An urgent laparotomy was performed. A giant, livid torted cystic MD with a narrow base extend-

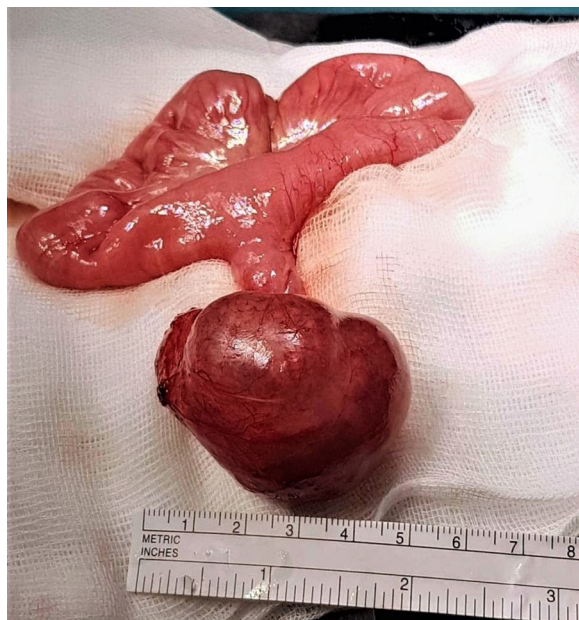ing from the antimesenteric wall of the ileum, 60 cm proximal of the ileocecal valve, was identified. It measured  $5.1 \times 4.2$  cm, was well-circumscribed, and lacked necrosis or hemorrhage (Fig. 2). No other intraabdominal pathology was identified. We resected the segment of the ileum bearing Meckel's diverticulum and anastomosed it in an end-to-end fashion. Histopathological examination confirmed the diagnosis of MD without gastric or pancreatic metaplasia. Postoperative recovery was uneventful, and the patient was discharged on the sixth postoperative day. A regular, 3-year follow-up revealed no complications.

## Ethics Statement

This study has been performed following the ethical standards of the Declaration of Helsinki (1964). The local institutional review board has the policy not to review case reports. Written informed consent was obtained from the patient's mother for anonymized patient information and images published in this article.



**Fig. 1A-B:** Coronal (A) and sagittal (B) reconstructive contrast-enhanced CT scan showing hypodense, round mass in the right hemiabdomen below the right liver lobe (red arrows), partially filled with air (white pointed arrow).



**Fig. 2.** Intraoperative findings showing twisted giant cystic Meckel's diverticulum.

## Discussion

The differential diagnosis of intra-abdominal cystic lesions in childhood is broad and includes cysts originating from the gastrointestinal tract, ovaries, or urinary system (5). Segmental cystic duplications of the alimentary tract, mesenteric and omental cysts, dermoid cysts, and ovarian cysts are among the nonparenchymatous intra-abdominal/pelvic cystic lesions in children (5). Although the characteristic radiological appearance of MD is a sacular structure attached to the antimesenteric border of the distal ileum, radiological diagnosis of a cystic MD is still a challenge. It should be noted that cystic MD is rarely the first choice to diagnose cystic lesions in the pediatric abdomen.

Based on a recent comprehensive systematic review, the MD's average length is 3.05 cm (3). A giant MD is termed if it is >5 centimeters (6). It was shown that the ratio of complications correlates with the size of the diverticulum (7). Giant diverticula occur in two relatively distinct forms: the elongated type and the ovoid or sacular type (8). The elongated type is the more common type

and is characterized by the same caliber as the ileum (8). This type can cause intestinal obstruction due to knotting around the small bowel (2). The ovoid or sacular type is less frequent, and some authors suggest that the term giant MD should be exclusively reserved for this type of MD (8).

The clinical presentation of patients with symptomatic MD varies, ranging from a hemorrhage or torsion to manifestations of intestinal obstruction, a palpable abdominal mass, or urinary symptoms (3). A giant MD can be identified infrequently due to its torsion, resulting in necrosis and perforation of a MD (5). In our case, incomplete twisting of a giant MD occurred around the diverticulum's base, relatively narrow compared to a giant diverticulum's length. The clinical presentation of our patient included abdominal pain, abdominal guarding, rebound tenderness, and vomiting, whose evaluation revealed a palpable cystic abdominal mass in the middle abdomen. The surgical approach depends on the size, location, and level of the surgeon's experience in minimal access surgery. The surgical treatment of choice is the resection of a segment of the adjacent ileum bearing the diverticulum.

## Conclusion

A giant cystic Meckel's diverticulum represents a rare cause of intra-abdominal/pelvic mass and should be considered in differential diagnosis. Timely surgical intervention reduces morbidity and provides the best clinical outcome.

**Authors' Contributions:** Conception and design: ZZ and SV; Acquisition, analysis and interpretation of data: ZZ, AJ, ISP and SV; Drafting the article: SV; Revising the article critically for intellectual content: ZZ, AJ, ISP and SV; Approved final version of the manuscript: ZZ, AJ, ISP and SV.

**Conflict of Interest:** The authors declare that they have no conflict of interest.

## References

1. Ludtke FE, Mende V, Kohler H, Lepsien G. Incidence and frequency or complications and management of Meckel's diverticulum. *Surg Gynecol Obstet.* 1989;169(6):537-42.

2. Opitz JM, Schultka R, Gobbel L. Meckel on developmental pathology. *Am J Med Genet A*. 2006;140(2):115-28.
  3. Hansen CC, Soreide K. Systematic review of epidemiology, presentation, and management of Meckel's diverticulum in the 21st century. *Medicine (Baltimore)*. 2018;97(35):e12154.
  4. Mohiuddin SS, Gonzalez A, Corpron C. Meckel's diverticulum with small bowel obstruction presenting as appendicitis in a pediatric patient. *JLS*. 2011;15(4):558-61.
  5. Oguzkurt P, Arda IS, Kayaselcuk F, Barutcu O, Oguzkurt L. Cystic Meckel's diverticulum: A rare cause of cystic pelvic mass presenting with urinary symptoms. *J Pediatr Surg*. 2001;36(12):1855-8.
  6. Farooq M, Rajesh A. Giant Meckel's diverticulum compressing root of mesentery - A rare cause of ileal gangrene - Case report and review of literature. *Int J Surg Case Rep*. 2017;38:53-6.
  7. Bani-Hani KE, Shatnawi NJ. Meckel's diverticulum: comparison of incidental and symptomatic cases. *World J Surg*. 2004;28(9):917-20.
  8. Cross VF, Wendth AJ, Phelan JJ, Goussous HG, Moriarty DJ. Giant Meckel's diverticulum in a premature infant. *Am J Roentgenol Radium Ther Nucl Med*. 1970;108(3):591-7.
-