

Fructose Metabolism Defects in Indian Children - Uncommon or Under-reported? - a Case Series

Nida Mirza¹, Ankita Maheshwari²

¹Department of Pediatrics, SAMC & PGI, Indore, India, ²Pediatric endocrinology, Department of Pediatrics, SAMC & PGI, Indore, India

Correspondence: ankitamaheshwari23@gmail.com; Tel.: + 7046370787

Received: ~~October 8 2021~~; **Accepted:** October 30 2023



Abstract

Objective – The objective of this case series is to report the varied manifestations of fructose metabolic defects across various age groups in Indian children. **Case Series** – We report 3 cases of fructose intolerance (1 male, 2 female) presenting at 17 months, 3.3 years and 10 months, with hypoglycaemia, recurrent metabolic acidosis, and abdominal distension with hepatomegaly, respectively. Weight was more affected than height in all of them: 1 child had hypoglycaemia and 2 of them had metabolic acidosis. Genetic tests confirmed the diagnosis with 2 patients having mutations in the FBP-1 gene and 1 mutation in the ALDO-B gene. Catch up growth was documented with resolution of symptoms in all with a fructose free diet. **Conclusion** – Fructose metabolic defect is a wide spectrum disorder which should be kept in mind in children with failure to thrive, recurrent hypoglycaemia and/or metabolic acidosis.

Key Words: Hypoglycaemia ■ Fructose 1,6 Bisphosphatase deficiency ■ Underweight.

Introduction

Fructose is a major sweetener in our daily diet, with a current trend of a global increase in its ingestion. Inborn errors of carbohydrate metabolism are a group of inherited disorders which include defects relating to glucose, galactose, fructose, and pyruvate (1). Response to dietary sugar can be different in children whose capacity to metabolize fructose is limited. Three inborn errors are known in the fructose metabolism pathway (2): essential or benign fructosuria due to fructokinase deficiency; hereditary fructose intolerance (HFI) due to Aldolase B deficiency; and fructose-1,6-bisphosphatase (F1,6 BP) deficiency due to fructose 1,6 bisphosphatase deficiency (F1,6 BPD) (Fig.1). Children with these disorders have normal growth and development during exclusive breastfeeding, but the introduction

of fructose, sucrose (disaccharide formed by fructose and glucose) can cause metabolic acidosis, vomiting, feeding difficulties, failure to thrive, hypoglycaemia, hepatomegaly and jaundice.

Here we present a case series of 3 children with these disorders presenting at various ages, with different manifestations.

Case 1

A boy, 1 year and 5 months old, the first born of a non-consanguineous marriage, with birth weight of 2.3 kg, presented with a history of multiple seizure episodes at 1 year, 1.3 and 1.5 years. There was documented hypoglycaemia during each episode of seizure. He had normal development with a non-contributory family and neonatal history. On examination he was underweight, there was frontal

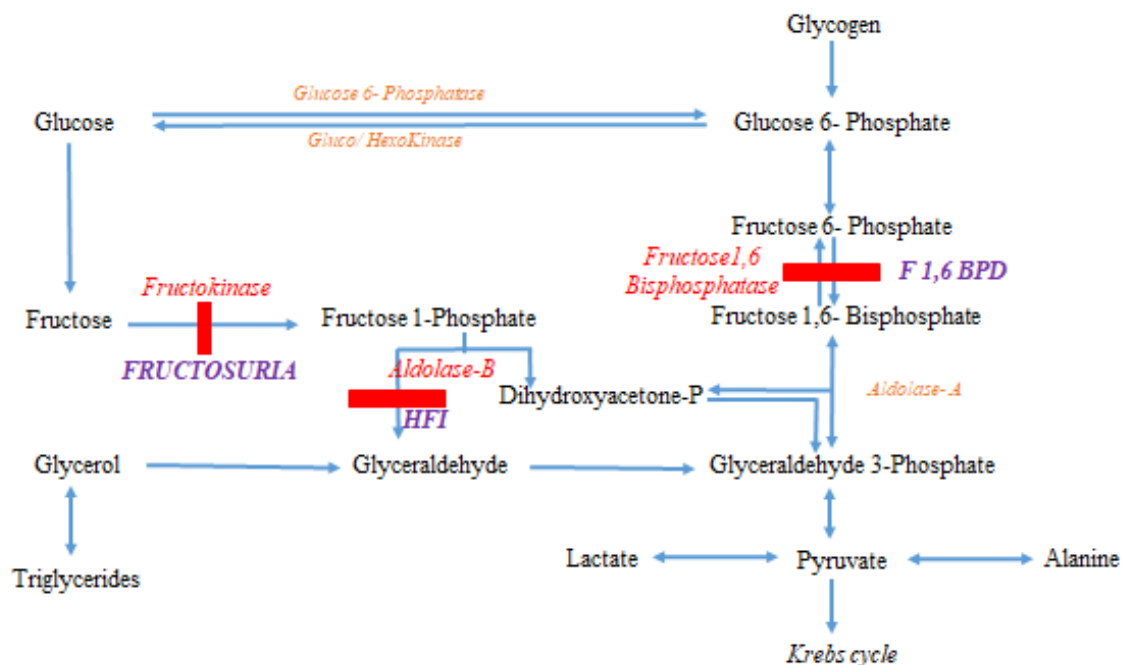


Fig. 1. Fructose metabolism Pathway.

bossing and pallor present with no organomegaly, and normal genitals. Hypoglycaemia was induced by overnight fasting (blood sugar 45 mg/dl) with collection of critical samples. He was found to have ketotic and acidotic hypoglycaemia (Table-2) with normal hormonal evaluation (normal growth hormone 12.9 ng/ml, cortisol 40.9 mcg/dl, insulin 0.02 IU/ml and c-peptide 0.8 ng/ml) with elevated triglycerides, lactate and uric acid. A genetic test [Next Generation Sequencing (NGS)] was sent to rule out metabolic defects, and revealed a homozygous mutation in Exon 8 of the *FBP-1* gene (c.841G>A). The parents were counselled and he was initiated on a fructose-free diet. Catch up in weight was documented with no hypoglycaemia events at 6 month follow-up.

Case 2

A girl, 3 years and 3 months old, the first born of a non-consanguineous marriage, presented with fever, vomiting (3-4 episodes) and rapid breathing for one day. There was no history of fever,

diarrhoea, polyuria, polydipsia, abdominal pain, or seizures. She had a birth weight of 3 kg with an unremarkable birth history. On detailed evaluation, this was found to be the 3rd episode with a similar type of complaints. The first 2 episodes were at 8 months and 2 years and required hospitalisation for rapid breathing (investigations suggested metabolic acidosis), with normal sugar and urine test results. Her episodes were precipitated by febrile illness and her symptoms resolved with symptomatic treatment. On examination, she was underweight and short, she had pallor without any icterus, clubbing, oedema or facial dysmorphism (Table 1). Her liver was palpable (5 cm below the coastal margin, soft). Investigations revealed metabolic acidosis with increased lactate, triglycerides and mildly raised liver enzymes. A genetic test (NGS) was sent to rule out metabolic defects and revealed a homozygous mutation in exon 8 of the *FBP-1* gene (c.841G>A) confirming the diagnosis. The parents were counselled to stop fructose rich foods in the diet, and she showed catch up growth with no acidosis episodes after dietary modifications.

Case-3

A ten-month old female, born at full term with a birth weight of 3 kg, presented with abdominal distension and had not been growing well for 2 months. There was no history of jaundice, vomiting, altered sensorium, abnormal movements, fever, decreased urine output, or swelling of any other part of body. On examination, she was active and playful, there was no icterus, pallor, oedema or clubbing but had hepatomegaly (liver span 8 cm). The tests showed that lactate, triglycerides and serum transaminase were mildly elevated (Table 2). Liver biopsy was

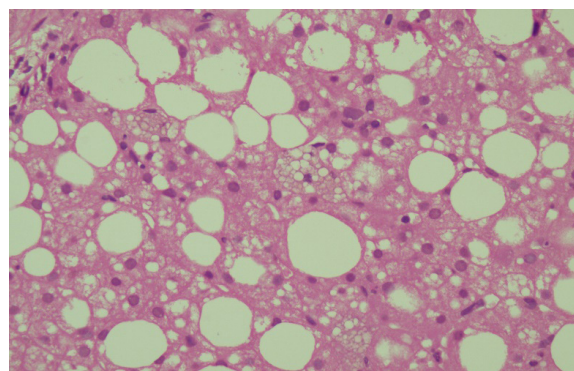


Fig. 2. Liver biopsy (Case-3) - Macro vesicular fatty changes in hepatocytes; Kupffer cells and histiocytes show distended cytoplasm (foamy appearance) (H & E stain; 100 × magnification)

Table 1. Clinical Details of Cases

	Case 1 (mos.)	Case 2 (mos.)	Case 3 (mos.)
Age at diagnosis	17	39	10
Onset of symptoms	12	8	8
Gender	Male	Female	Female
Weight (kg)	7.6	11	6.5
Weight z-score	-3.1 SD	-2.1 SD	-2.2 SD
Height (cm)	81	88	67
Height z-score	-0.1 SD	-2.3 SD	-1.8 SD
Facial features	Frontal bossing	Normal	Normal
Hepatomegaly	No	Yes	Yes

performed which showed macro vesicular fatty changes in most of the hepatocytes, with Kupffer cells and histiocytes showing distended cytoplasm imparting a foamy appearance, suggestive of some storage disorder (Fig. 2). A genetic test (NGS) was sent to confirm the diagnosis, which revealed the diagnosis of HFI (Homozygous missense variation in Exon 5 of the *ALDOB* gene; c.448G>C). A fructose free diet was initiated and she presented with improvement in growth and clinical features.

Clinical details and investigations of all cases are enumerated in Table 1 and Table 2 respectively.

Table 2. Laboratory Tests

Tests	Normal value	Case-1	Case-2	Case-3
Blood sugar (mg/dl)	>70	45	98	85
pH	7.25-7.35	7.19	6.97	7.23
HCO ₃ (mEq/L)	20-24	12.0	5.2	17.5
Ammonia (mcg/dl)	<65	56	44	60
Lactate (mmol/l)	<2	8.3	5.6	6.9
Uric acid (mg/dl)	3.5-7.2	9.0	3.8	8.3
Serum Creatinine (mg/dl)	0.5-1.2	0.17	0.2	0.18
Haemoglobin (mg/dl)	12-14	10.2	11.2	10.9
SGPT/ SGOT (U/l)	<40 / <36	36/33	60/58	64/43
Total Cholesterol (mg/dl)	<200	197	128	136
Triglycerides (mg/dl)	<130	202	40	278
Mutation*	-	<i>FBP-1</i>	<i>FBP-1</i>	<i>ALDOB</i>

*Next Generation Sequencing (NGS)

Discussion

Fructose metabolism defects are inherited disorders characterized by hypoglycaemia (lethargy, seizures, coma) and lactic acidosis, with the common precipitating factors being infections, fasting and vomiting. The pathway of fructose metabolism defect is depicted in Fig. 1.

Fructose biphosphatase deficiency is an autosomal recessive disorder characterised by impaired glucose production from gluconeogenic precursors (including dietary fructose) in the liver (3). Childhood manifestations include hypoglycaemia and lactic acidosis, with triggering factors being fever, diarrhoea, vomiting and prolonged fasting. It was first described in 1970 (4) with the first mutation identified in 1995 (5). Hereditary fructose-1,6-bisphosphatase deficiency can present with hypoglycaemia (low blood sugar), breathing difficulties (apnoea), hyperventilation, ketosis (a sign of incomplete sugar metabolism), and lactic acidosis (6) due to the impaired capacity of the liver and other organs to metabolize glycogen (one of the major energy reserves of the body). The majority of patients with FBPase deficiency experience normal growth, but may have hypoglycaemic brain damage if diagnosis is unaddressed (7).

Case 1 here had classic symptoms, as reported in the literature (8) and the patient showed improvement in symptoms and catch-up growth on a fructose free diet. Our second case had no hypoglycaemia events as classically reported, but had recurrent episodes of metabolic acidosis with growth failure. The possible reason for this is that the disease has a wide and non-specific spectrum of symptoms, and the patient might not exhibit all symptoms. In some cases a high dose of fructose is required to cause hypoglycaemia (9) which might not have occurred in our patient at each episode.

HFI is caused by a deficiency of Aldolase B, a key enzyme in the fructose pathway which splits F-1-P into dihydroxyacetone phosphate and glyceraldehyde in the liver, small intestine and proximal renal tubule (10). HFI typically manifests when

fructose- and sucrose-containing foods are introduced in the course of weaning young infants from breast milk (11). Manifestations include nausea, bloating, vomiting, sweating, abdominal pain, and growth retardation.

In Case 3, there was no history of vomiting or hypoglycaemia, however there was significant steatosis with foamy cells on the liver biopsy, so in the absence of typical symptoms it could have been misdiagnosed as some storage disorder. There is literature describing that in individuals with HFI it may manifest as chronic liver and/or renal disease if they do not adhere to the recommended dietary restrictions (12). However, long-term natural history studies in untreated individuals are lacking. HFI is occasionally recognized in childhood when hepatomegaly or growth delay is found (13).

Diagnosis can be suspected from clinical features with a critical sample (at the time of hypoglycaemia) showing ketosis and acidosis. Liver function tests are usually not affected in F16 BPD, whereas elevated transaminases and liver failure can be seen in HFI. Genetic counselling should be offered for these patients, and antenatal diagnosis should be attempted in subsequent pregnancies.

Conclusion

Fructose metabolic defects should be suspected in children with failure to thrive and recurrent metabolic acidosis. Misdiagnosis is quite common because of the rarity of the condition and the fact that it closely mimics other inherited enzymatic deficiencies.

Acknowledgement: NA

Author's Contribution: NM conceptualised and designed; acquisition analysis was done by AM; Data interpretation was done by NM and AM; NM and AM drafted the article; NM revised the article for intellectual concept; AM approved the final version of manuscript.

Conflict of Interest: The authors declare that they have no conflict of interest.

References

1. Agana M, Frueh J, Kamboj M, Patel DR, Kanungo S. Common metabolic disorder (inborn errors of metabolism) concerns in primary care practice. *Ann Transl Med.* 2018;128(24). doi:org/10.21037.atm.2018.12.34.
 2. Hannou SA, Haslam DE, McKeown NM, Herman MA. Fructose metabolism and metabolic disease. *J Clin Invest.* 2018;128(2):545-555. doi: 10.1172/JCI96702.
 3. Lebigot E, Brassier A, Zater M, Imanci D, Feillet F, Thérond P, de Lonlay P, Boutron A. Fructose 1, 6-bisphosphatase deficiency: clinical, biochemical and genetic features in French patients. *Journal of Inherited Metabolic Disease: Official Journal of the Society for the Study of Inborn Errors of Metabolism.* 2015;38(5):881-7. doi: 10.1007/s10545-014-9804-6.
 4. Baker L, Winegrad AI. Fasting hypoglycaemia and metabolic acidosis associated with deficiency of hepatic fructose-1,6-diphosphatase activity. *Lancet.* 1970;2(7662):13-6. doi: 10.1016/s0140-6736(70)92474-8.
 5. El-Maghrabi MR, Lange AJ, Jiang W, Yamagata K, Stofel M, Takeda J, et al. Human fructose-1,6-bisphosphatase gene (FBP1): exon-intron organization, localization to chromosome bands 9q22.2-q22.3, and mutation screening in subjects with fructose-1,6-bisphosphatase deficiency. *Genomics.* 1995;27(3):520-5. doi: 10.1006/geno.1995.1085.
 6. Kılıç M, Kasapkara ÇS, Yılmaz DY, Özgül RK. Exon 2 deletion represents a common mutation in Turkish patients with fructose-1,6-bisphosphatase deficiency. *Metab Brain Dis.* 2019;34(5):1487-1491. doi: 10.1007/s11011-019-00455-8.
 7. Moey LH, Abdul Azize NA, Yakob Y, Leong HY, Keng WT, Chen BC, et al. Fructose-1,6-bisphosphatase deficiency as a cause of recurrent hypoglycemia and metabolic acidosis: Clinical and molecular findings in Malaysian patients. *Pediatr Neonatol.* 2018;59(4):397-403. doi: 10.1016/j.pedneo.2017.11.006.
 8. Bijarnia-Mahay S, Bhatia S, Arora V. Fructose-1,6-Bisphosphatase Deficiency. 2019. In: Adam MP, Feldman J, Mirzaa GM, et al., editors. *GeneReviews*®. Seattle (WA): University of Washington, Seattle; 1993-2023. Available from: <https://www.ncbi.nlm.nih.gov/books/NBK550349/>
 9. Boesiger P, Buchli R, Meier D, Steinmann B, Gitzelmann R. Changes of liver metabolite concentrations in adults with disorders of fructose metabolism after intravenous fructose by 31P magnetic resonance spectroscopy. *Pediatr Res.* 1994;36(4):436-40. doi: 10.1203/00006450-199410000-00004.
 10. Odièvre M, Gentil C, Gautier M, Alagille D. Hereditary fructose intolerance in childhood. Diagnosis, management, and course in 55 patients. *Am J Dis Child.* 1978;132(6):605-8. doi: 10.1001/archpedi.1978.02120310069014.
 11. Ali M, Rellos P, Cox TM. Hereditary fructose intolerance. *J Med Genet.* 1998;35(5):353-65. doi: 10.1136/jmg.35.5.353.
 12. Buziau AM, Schalkwijk CG, Stehouwer CDA, Tolan DR, Brouwers MCGJ. Recent advances in the pathogenesis of hereditary fructose intolerance: implications for its treatment and the understanding of fructose-induced non-alcoholic fatty liver disease. *Cell Mol Life Sci.* 2020;77(9):1709-19. doi: 10.1007/s00018-019-03348-2.
 13. Mock DM, Perman JA, Thaler M, Morris RC Jr. Chronic fructose intoxication after infancy in children with hereditary fructose intolerance. A cause of growth retardation. *N Engl J Med.* 1983;309(13):764-70. doi:10.1056/NEJM198309293091305.
-