

Duodenal Atresia with Apple-peel Intestinal Atresia: a Case with Favorable Outcome

Banjac Lidija^{1,3}, Banjac Boban^{2,3}, Haliti Azem⁴, Majic Velibor⁵

¹Department of Neonatology, Clinical Center Montenegro, Children's Diseases Institute, Podgorica, Montenegro, ²Department of Radiology, Clinical Center Montenegro, Podgorica, Montenegro. ³University of Montenegro, Faculty of Medicine, Podgorica, Montenegro, ⁴Clinic of Gynecology and Obstetrics, Clinical Center Montenegro, Podgorica Montenegro, ⁵Department of Paediatric Surgery, Clinical Center Montenegro, Children's Diseases Institute, Podgorica, Montenegro

Correspondence: lidija.banjac@kccg.me; Tel.: + 382 69 305533

Received: Apr 4 2024; **Accepted:** July 5 2024

Abstract

Objective – Duodenal atresia with apple-peel intestinal atresia remains a difficult and complex condition, even with advances in medical and surgical therapies. Due to the significant difference in etiology, the association between these two types of atresia is very rare and is associated with a high rate of mortality. Only twelve of these cases have been described so far in English literature, most often with a poor outcome. Our patient survived and is doing well. **Case Report** – Here, we present a premature infant in whom intestinal atresia was suspected prenatally. On the first day of life, based on clinical, radiographic and ultrasound examination, suspicion was confirmed and surgical intervention was performed. It was discovered that the proximal part of the duodenum blindly ends with a large dilation. The proximal jejunum also ends blindly and the distal small intestine wraps around a single mesenteric vessel in a spiral fashion reminiscent of an “apple-peel.” At the first operation (on the first day of life), a double enterostomy of the proximal duodenum and the proximal jejunum was performed. On the second operation (on day 10), the continuity of the digestive intestine was established by end-to-end duodeno-jejunal anastomosis. Progress in body mass was confirmed during the postoperative period and normal stool was formed on a regular basis. **Conclusion** – Based on our case, possible reasons for the good outcome of patients with these rare forms of intestinal atresia are prenatal suspicion, early postnatal diagnosis, and early surgical intervention. Further studies should investigate the possibility of a common cause of duodenal atresia and apple-peel atresia to facilitate early diagnosis and early treatment.

Key Words: Duodenal Atresia ■ Apple-Peel Atresia ■ Premature Infant.

Introduction

Duodenal atresia is the most common congenital cause of neonatal intestinal obstruction, with an incidence of 1 in 5000-10,000 live births. Apple-peel intestinal atresia, also known as Christmas tree intestinal atresia, is a rare form of intestinal atresia. It consists of a proximal jejunum ending in a blind pouch and a distal small bowel wrapped around its vascular supply in a spiral manner similar to an “apple-peel” (1). Santulli and Blanc provided the initial description of it in 1961 (2). The incidence

of apple-peel intestinal atresia is 0.7%–0.8% in 10,000 live births (1, 3). Apple-peel intestinal atresia is usually an isolated malformation (4).

The absence of recanalization at gestational week 6 is one of the most widely accepted theories on the origin of duodenal atresia (5, 6). However, apple-peel intestinal atresia is caused by an interruption of vascular supply at later stages of gestation (5). Due to the significant difference in etiology, the association of duodenal atresia with apple-peel atresia is very rare. A familiar occurrence of combined duodenal atresia and apple-peel atresia has

been reported, which supports the possibility of a genetic cause for such an association (7). Although there have been recent advances in the outcome, it is associated with higher rates of morbidity and mortality (8). Due to this anatomy, patients are at increased risk for short bowel syndrome and intestinal failure (9).

This report describes a rare case of duodenal atresia with apple-peel intestinal atresia in a premature infant with a favorable outcome. So far, only twelve such cases have been described in English literature (5).

Case Report

A preterm infant in the first hour of life was admitted to the neonatal intensive care unit due to a possible congenital intestinal abnormality. An abdominal ultrasound at 27/28 weeks of gestation revealed two hypoechoic formations (a dilated stomach and a dilated duodenum) as well as the distal small intestine (Fig. 1A). Polyhydramnion was also discovered through subsequent tests. This raised the suspicion that it was a congenital anomaly of the intestine. The mother was a 31-year-old woman with no significant medical history or

family history of intestinal atresia. The preterm infant (36 weeks of gestation), born naturally, had a body weight (BW) of 2.540 kg and an Apgar score of 8/8.

On admission, nearly 10 ml of liquid yellow-green gastric content was evacuated through the nasogastric tube. The infant was eupnoic. The abdomen was at the level of the thorax and was soft and mobile during breathing. The first X-ray of the abdomen showed two air areas (dilated stomach and duodenum), while the rest of the abdomen was gasless, indicating intestinal atresia (Fig. 1B). A contrast enema showed a small colon. An echocardiographic examination revealed no structural abnormalities. Flow through the ovale foramen and the arteriosus duct is recorded.

Following the diagnosis, an exploratory laparotomy was performed on the first day of life. The abdominal cavity was accessed through a right transversal supraumbilical laparotomy. The atresia of the small intestine was clearly visible after opening the abdominal cavity due to the type of apple-peel intestinal atresia (Fig. 2A). During exploration of the digestive tube, it was discovered that the proximal part of the duodenum blindly ends with a large dilatation. The proximal jejunum also ends blindly, and the distal small intestine wraps around

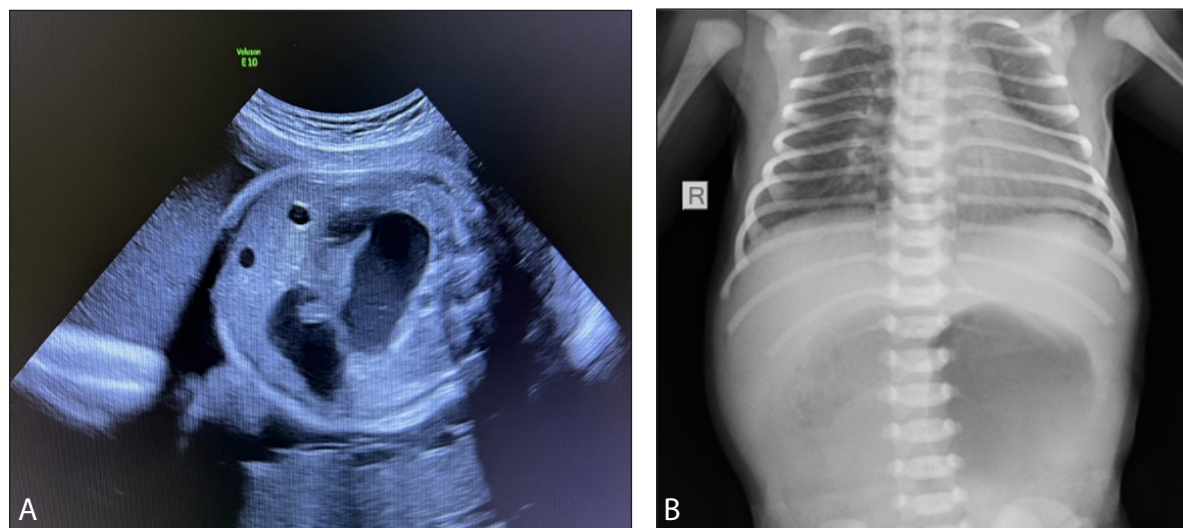


Fig. 1. A. Antenatal ultrasonography 27/28 week GA revealed two hypoechoic formations (a dilated stomach and a dilated duodenum) and a distal small bowel; B. X-ray abdomen showed “double-bubble” sign, while the rest of the abdomen was gasless.

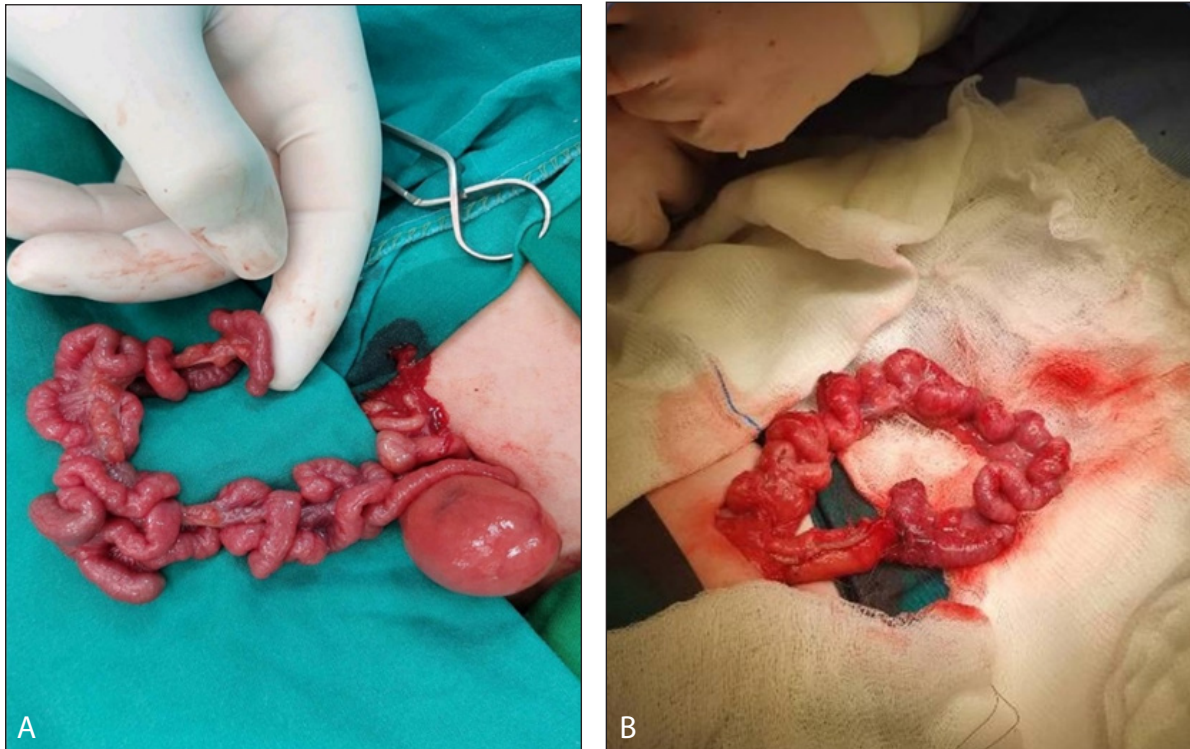


Fig. 2. A. Duodenal atresia with apple-peel small intestinal atresia. B. Complete the end-to-end duodeno-jejunal anastomosis.

a single mesenteric vessel (absence of a superior mesenteric artery) in a spiral manner similar to an apple-peel (Fig. 2A).

After inspecting the passage of the distal part of the intestine, a double enterostomy of the proximal duodenum and proximal jejunum was performed on the front abdominal wall. After the operation, the patient continued to recover in our intensive care unit. After four days of mechanical ventilation, she was extubated, receiving oxygen through a nasal cannula, and had normal saturation. An extensive hydrolyzate formula was continuously administered (5 ml/kg) through a tube inserted into the distal stoma on the fifth postoperative day, together with parenteral nutrition.

A second operation was performed on the 10th day of life. Considering that the proximal end of the duodenum was extremely dilated, “tapering” is performed with a linear stapler with a length of 8 cm. The distal end of the intestine was prepared and the end-to-end duodeno-jejunal anastomosis

was performed in two layers. A large meso defect was reconstructed with individual sutures (Fig. 2B).

Due to the absence of spontaneous stools, an enema was administered on the seventh postoperative day. Enteral intake was delayed for two weeks due to regurgitation of the contents through the nasogastric tube. Then the feeding with an extensive protein hydrolyzate formula was started using an enteral pump in the amount of 3 ml/kg with a gradual increase, which was well tolerated. Because the patient tolerated enteral nutrition well, oral nutrition was started quickly, first with infant formulas and then with breast milk.

Throughout the postoperative period, progress in body mass was verified and normal stools formed on a regular basis. The patient was discharged in good general condition for further outpatient follow-up at the primary center. After discharge, she continued to feed on his mother’s milk. After the sixth month, solid foods were also introduced.

Body mass is increasing satisfactorily and stools are regular.

Discussion

Duodenal atresia is the most common congenital cause of intestinal obstruction. Apple-peel intestinal atresia is a rare form of congenital intestinal atresia. This report describes a rare case of duodenal atresia with apple-peel intestinal atresia in a preterm infant with a favorable outcome. Due to the significant difference in etiology, the association of duodenal atresia with apple-peel intestinal atresia is very rare. So far, only twelve cases have been described in the English literature (5). Here, we present the thirteenth case of the association of these congenital anomalies. This case is noteworthy to report because the combination of such special types of intestinal atresia has a poor prognosis.

In our patient, a congenital intestinal anomaly was suspected prenatally on the basis of fetal ultrasound (“double bladder” sign, small calibre of other intestines, polyhydramnios). The return of a large amount of liquid to the nasogastric tube in the first hour of life was in favor of this. Prenatal diagnostics are crucial, in addition to clinical presentation, in making the diagnosis of intestinal atresia. Approximately half (52%) of all cases are identified prenatally on fetal ultrasound with the typical presence of a ‘double bubble’ sign in the upper abdomen, suggesting a dilated fluid-filled stomach and duodenum (10). In cases where prenatal suspicion is not raised, this type of intestinal atresia is clinically manifested in the first days of life with complaints of vomiting, yellow discoloration of the skin, and failure to pass meconium since birth (4). Our patient was a premature infant, and studies confirm that patients with these anomalies have a high incidence of prematurity (70%) (11).

In addition, these babies have a lower BW. The BW of our patient was 2.540 kg. Half of the infants have a BW of less than 2.500 kg, which is associated with polyhydramnios because the fetus cannot absorb nutrients from the amniotic fluid (12). Our patient had no other associated anomalies except

the absence of a superior mesenteric artery. Other studies describe that duodenal atresia is often associated with other anomalies, Apple-peel intestinal atresia is usually an isolated malformation (1). The operative treatment of our patient was performed in two stages. The first operation, an early exploratory laparotomy and surgery to correct the blockage (dividing the blockage), was performed on the first day of life. Two stomas were performed. The second intervention, which involved reconnecting the intestine, was carried out on the 10th day of life. Other authors also believe that in infants with suspected symptoms of intestinal obstruction, an exploratory laparotomy is required immediately, followed by effective surgical therapy to remove the obstruction and restore normal function to the small intestine (13, 14).

After the first operation, the patient was fed a special formula (extensive hydrolyzate) through the stoma and after the second operation, she was fed mother’s milk orally. Breastfeeding continued after hospital discharge. After the sixth month, solid foods were introduced. Her body mass is increasing satisfactorily and the stools are regular.

Compared to our previous patient (the fourth case in the English literature), this patient had a longer gestation, a higher BW, and the operation was performed earlier (on the first day of life), before the appearance of other clinical signs of atresia. We think these are the reasons for the favorable outcome for our patient. The authors agree that prematurity, low BW, associated congenital abnormalities, sepsis, and delayed presentation are the main risk factors for postoperative mortality and morbidity (4, 15).

Conflict of Interest: The authors declare that they have no conflict of interest.

Conclusions

Duodenal atresia with apple-peel intestinal atresia remains a difficult and complex condition, even with advances in medical and surgical therapies. Based on our case, possible reasons for the good outcome of patients with these rare forms of

intestinal atresia are prenatal suspicion, early post-natal diagnosis, and early surgical interventions. Poor prognostic indicators are prematurity, low BW, sepsis, and associated congenital anomalies. Further studies should investigate the possibility of a vascular accident as a mutual cause of both duodenal atresia and apple-peel atresia to facilitate early diagnosis and early treatment.

References

1. Bin Arif T, Ahmed J, Malik F, Nasir S, Ali A. An Atypical Variant of Apple Peel Atresia: Reporting a Rare Case. *Cureus*. 2019;11(11):e6047. doi:10.7759/cureus.6047. PMID: 31819834; PMCID: PMC6886733.
2. Santulli TV, Blanc WA. Congenital atresia of the intestine: pathogenesis and treatment. *Ann Surg*. 1961;154(6):939-48. PMID: 14497096; PMCID: PMC1465932.
3. Alnosair AA, Naga MI, Abdulla MR, Al-Salem AH. Congenital duodenal atresia with 'apple-peel configuration' of the small intestines and absent superior mesenteric artery: A case report and review of literature; *J Ped Surg Case Reports* (2014) 215-8.
4. Stollman TH, de Blaauw I, Wijnen MH, van der Staak FH, Rieua PN, Draaisma JM, Wijnena RM. Decreased mortality but increased morbidity in neonates with jejunoileal atresia; a study of 114 cases over a 34-year period. *J Pediatr Surg*. 2009;44:217-21. doi: 10.1016/j.jpedsurg.2008.10.043. PMID: 19159746.
5. Molino Gahete JA, López Fernández S, Oliver B, Boix H, Rocha O, López M, Guillén G. Duodenal atresia with apple peel associated with congenital diaphragmatic hernia: an exceptional case and a literature review. *Cir Pediatr*. 2022;35(1):31-5. English, Spanish. doi: 10.54847/cp.2022.01.16. PMID: 35037438.
6. Pathak M. Pathak M, Narula D. A case of duodenal atresia with apple peel appearance: challenging the current embryology. *J Clin Neonatol*. 2014;3(2):112-4. doi: 10.4103/2249-4847.134709. PMID: 25024980; PMCID: PMC4089124.
7. Pumberger W, Birnbacher R, Pomberger G, Deutinger J. Duodeno-jejunal atresia with volvulus, absent dorsal mesentery, and absent superior mesenteric artery: a hereditary compound structure in duodenal atresia? *Am J Med Genet*. 2002;109(1):52-5. doi: 10.1002/ajmg.10309. PMID: 11932992.
8. Lee SH, Cho YH, Kim HY, Park JH, Byun SY. Clinical experience of complex jejunal atresia. *Pediatr Surg Int*. 2012;28:1079-83.
9. Dao DT, Demehri FR, Barnewolt CE, Buchmiller TL. A new variant of type III jejunoileal atresia. *J Pediatr Surg*. 2019;54(6):1257-1260. doi: 10.1016/j.jpedsurg.2019.02.003. Epub 2019. PMID: 30827488; PMCID:PMC6545255.
10. Rattan KN, Singh J, Dalal P. Neonatal Duodenal Obstruction: A 15-Year Experience. *J Neonatal Surg*. 2016;5(2):13. PMID: 27123397; PMCID:PMC4841369.
11. Gavopoulos, Ch Limas, P. Avtzoglou, G. Tsikopoulos, A. Violaki, G. Grigoriadis, et al. Operative and postoperative management of congenital duodenal obstruction: a 10 year experience. *Pediatr Surg Int*, 8 (1993), pp. 122-4
12. Haeusler MC, Berghold A, Stoll C, et al. Prenatal ultrasonographic detection of gastrointestinal obstruction: results from 18 European congenital anomaly registries. *Prenat Diagn*. 2002;22(7):616-23.
13. Gupta S, Gupta R, Ghosh S, Gupta AK, Shukla A, Chaturvedi V, Mathur P. Intestinal Atresia: Experience at a Busy Center of North-West India. *J Neonatal Surg*. 2016 10;5(4):51. doi:10.21699/jns.v5i4.405. PMID: 27896159; PMCID:PMC5117274
14. Balineni P, Kamal S, Manickam P, Shivaji K. Apple peel atresia: a case report. *Int Surg J*. 2019;6:1821-3.
15. Deguchi K, Tazuke Y, Matsuura R, Nomura M, Yamanaka H, Soh H, Yoneda A. Factors Associated With Adverse Outcomes Following Duodenal Atresia Surgery in Neonates: A Retrospective Study. *Cureus*. 2022;14(2):e22349. doi: 10.7759/cureus.22349. PMID: 35371797; PMCID: PMC8936229.